

12-1953

# Histopathology of Bovine Mastitis, The

C.F. Helmboldt

*University of Connecticut - Storrs*


E.L. Jungherr

*University of Connecticut - Storrs*

W.N. Plastridge

*University of Connecticut - Storrs*

Follow this and additional works at: <https://opencommons.uconn.edu/saes>

 Part of the [Dairy Science Commons](#), [Veterinary Anatomy Commons](#), [Veterinary Microbiology and Immunobiology Commons](#), [Veterinary Pathology and Pathobiology Commons](#), and the [Veterinary Physiology Commons](#)

## Recommended Citation

Helmboldt, C.F.; Jungherr, E.L.; and Plastridge, W.N., "Histopathology of Bovine Mastitis, The" (1953). *Storrs Agricultural Experiment Station*. 45.

<https://opencommons.uconn.edu/saes/45>

THE HISTOPATHOLOGY  
of  
BOVINE MASTITIS

C. F. HELMBOLDT, E. L. JUNGHERR AND W. N. PLASTRIDGE

Department of Animal Diseases

STORRS AGRICULTURAL EXPERIMENT STATION

College of Agriculture, University of Connecticut

Storrs, Connecticut

## CONTENTS

	Page
INTRODUCTION	5
REVIEW OF LITERATURE	5
Histology	5
<i>The Udder of the Lactating Cow</i>	5
ALVEOLAR EPITHELIUM	6
INTERALVEOLAR TISSUE	6
DUCTAL SYSTEM	6
CISTERN OF THE UDDER	7
TEAT CISTERN AND TEAT	7
<i>The Udder at Time of First Conception</i>	8
<i>Changes of Udder During Pregnancy</i>	9
<i>Changes During Involution</i>	9
<i>Cytologic Aspects of Alveolar Epithelium</i>	9
<i>Colostrum Corpuscles</i>	9
<i>Corpus Amylaceum</i>	10
<i>Supramammary Lymph Nodes</i>	10
Histopathologic Changes in the Udder	10
<i>Historical Considerations</i>	10
<i>Classification of Mastitis</i>	11
<i>Acute Mastitis</i>	12
<i>Necrotic Mastitis</i>	14
<i>Suppurative Mastitis</i>	14
<i>Chronic Mastitis</i>	15
Specific Mastitides	15
<i>Brucellosis Mastitis</i>	15
<i>Leptospiral Mastitis</i>	16
<i>Staphylococcic Mastitis</i>	16
<i>Streptococcic Mastitis</i>	17
<i>Viral Mastitis</i>	18
<i>Cryptococcal Mastitis</i>	19
<i>Mycobacterial Mastitis</i>	19
The Supramammary Lymph Node in Mastitis	20
Leukocytes in Udder and Milk	20
Pathogenesis	20
MATERIALS AND METHODS	22

	Page
<b>RESULTS</b>	25
<b>Histologic Observations</b>	25
<i>Sebaceous Glands</i>	25
<i>Basket Cells</i>	26
Alveolar Epitheilum	26
Leukocytes	26
Corpora Amylacea	28
Colostrum Bodies	28
Ventral Levels of the Udder	29
<b>Pathologic Observations</b>	29
Classification	29
<b>GENERAL HISTOLOGIC FEATURES</b>	30
Acute Mastitis	30
Chronic Mastitis	32
<b>HISTOPATHOLOGY WITH RESPECT TO ETIOLOGY</b>	32
Staphylococcic Mastitis	32
Coliform Mastitis	34
Corynebacterial Mastitis	34
Streptococcic Mastitis	35
<b>PATHOGENESIS</b>	40
<b>VIRAL MASTITIS</b>	42
<b>INCIDENTAL MASTITIS</b>	42
Silver Oxide Mastitis	43
<b>SUPRAMAMMARY LYMPH NODES</b>	43
<b>SUMMARY AND CONCLUSIONS</b>	45
Normal Udders	45
Mastitic Udders	45
Acute Mastitis	45
Chronic Mastitis	46
Etiology and Histopathology	46
Lymph Nodes	47
<b>BIBLIOGRAPHY</b>	48



# The Histopathology of Bovine Mastitis

C. F. HELMBOLDT, \* E. L. JUNGHER\*\* AND W. N. PLASTRIDGE\*\*

## INTRODUCTION

Histopathologic study of the bovine udder was pursued rather intensely by German and Swiss investigators during the past century. As early as 1886 Kitt (1886) dismissed further pathologic investigations as repetitious and advocated a bacteriologic study of bovine mastitis. This appeared to be the trend at the time as the discovery that mastitis was a definite reproduceable entity (Franck 1876, Kitt 1882), was followed by a veritable avalanche of bacteriologic treatises. Histopathology was chiefly limited to "gelber Galt" as streptococcic mastitis was then known. Other bacteriologic forms of the disease were given relatively little histologic attention. However, recent advances in the bacteriologic differentiation of the various mastitides have suggested that histopathologic examination of the udder with respect to etiology be reviewed. Since all the commonly encountered forms of mastitis were present in a large dairy herd which was accessible for detailed study for a period of 20 years, it was felt that a histopathologic review would reveal new aspects or substantiate previously proposed interpretations. Of further interest was the fact that during the period the herd originally was infected with *Str. agalactiae* (agalactiosis) which disease was subsequently eliminated, only to see other forms of mastitis arise.

## REVIEW OF LITERATURE

The mammary gland has been reported to undergo histoanatomic changes in accord with the various phases of the reproductive cycle (Boyd 1947, Emmerson 1946). In addition, histologic variations were noted in recently-milked glands as compared to distended glands (Richardson 1949-50). Since such characteristics could be interpreted as a pathologic significance, the normal histologic features of the udder must be considered.

### Histology

The mammary gland has been classified as a tubulo-alveolar gland (Nieberle and Cohrs 1931, Trautmann and Fiebiger 1931, Espe 1946) of the apocrine type (Maximow and Bloom 1938, Sobotta and Piersol 1930) originating from the embryonic skin (Turner 1933) and strongly resembling sweat glands microscopically (Benda 1894).

*Udder of the Lactating Cow.* The basic unit of the mammary gland of the lactating cow has been designated as a lobule which consists of

\* Associate Professor of Animal Diseases.

\*\* Professor of Animal Diseases.

secretory and supportive tissues with an excretory duct. The secretory portions, the alveoli and alveolar ducts, have been described as consisting of an outer layer of myoepithelial cells, a basement membrane, and a lining of epithelial cells usually known as alveolar epithelium (Fürstenberg 1868, Maximow and Bloom 1938).

**ALVEOLAR EPITHELIUM.** The alveolar epithelium was described by Fürstenberg (1868) and Lenfers (1907) as "Pflasterepithelium," which translated literally is squamous epithelium, according to DeVries (1946). However, most descriptions considered the epithelium to be a single layer of cuboidal cells (Kehrer 1871, Kolessnikow 1877, Ernst 1909, Zwart 1911, Lund 1931, Holm 1937, Kwong 1940), although multi-layered areas were reported by Wulff (1889) and Gibbons (1938).

**INTERALVEOLAR TISSUE.** The alveolar epithelium was described as resting on an inconspicuous basement membrane (*membrana propria*) (Fürstenberg 1868, Ibel 1904, Lenfers 1907, Lund 1931, Nieberle and Cohrs 1931, Turner 1933, Espe 1946) which consisted of transparent connective tissue (Winckler 1877, Jaskowsky 1880) or endothelial cells (Raubert 1879). Kolessnikow (1877) mentioned that amidst the alveolar epithelium were polygonal cells which he apparently considered to be *membrana propria*.

The basket cells (*Korbzellen*) were described by Holm (1937) as having pale elongated nuclei with granular chromatin. They were designated as myoepithelial cells by Trautmann and Fiebiger (1931) since they resembled the myoepithelial cells of the sweat glands (Sobotta and Piersol 1930). Use of Van Gieson's technique showed them to be muscle cells (Benda 1894); the function of squeezing out the milk from the alveoli was ascribed to these cells by Zwart (1911) and Richardson (1949-50).

The exact location of the basket cells has been a controversial issue. They have been variously reported to lie outside the basement membrane (Richardson 1949-50), within the alveolar epithelium (Kolessnikow 1877, Sobotta and Piersol 1930, Gibbons 1938), or to be actually the basement membrane itself (Trautmann and Fiebiger 1931).

The remaining interalveolar tissues have been described as consisting of white fibrous tissue, blood capillaries, lymph spaces and nerves, although the latter were not seen by Fürstenberg (1868) and Holm (1938).

A recent approach considered the interalveolar tissue as a unit (Boyd 1947). This unit was designated periductal tissue (*periacinar* and *pericanalicular*) and should not be dissociated from the epithelial structure (Moore 1944, Boyd 1947). Another theory proposed that the periductal tissue underwent mucoid degeneration when the secretory portions began to swell in anticipation of parturition (Ingleby 1942). Photomicrographs (Maximow and Bloom 1938) of involuted mammary tissue supported this theory as lighter tissue was seen about the ducts of atrophied lobules, suggesting a specialized type (Maximow and Bloom 1938, Richardson 1947-48).

The lobules, which formed a lobe, were shown to be divided from one another by a supportive framework of white fibrous tissue, blood and lymph vessels, collecting ducts, and nerve fibers. In addition, the lobes were separated by yellow elastic tissue (Holm 1937).

**DUCTAL SYSTEM.** The excretory ducts of the udder were designated by Turner (1933) in order of increasing size, as the intercalary, the interlobular, and the interlobar ducts. The intercalary duct was shown

to be lined by a single-layered alveolar epithelium and thus was considered to have a secretory as well as an excretory function. The other ducts were found to be lined by double-layered epithelium according to Nieberle and Cohrs (1931) and Holm (1937); the inner or basic layer consisted of cuboidal cells while the outer layer, which faced the lumen, tended to be made up of columnar-type cells (Turner 1933). Nieberle and Cohrs (1931) and Holm (1937) reported that the intralobular and interlobular ducts were also lined with single-layered alveolar epithelium.

Uncertainty existed with respect to the structure adjacent to the epithelium. One group of investigators (Kolessnikow 1877, Benda 1894, Lund 1931, Nieberle and Cohrs 1931) reported that the ductal epithelium rested on the basement membrane, whereas Michaelis (1898) and Martin (1902) found this membrane difficult or impossible to see. In one instance (Wirz 1913) it was referred to as an endothelial membrane. Further confusion resulted in that some investigators saw the basement membrane becoming fainter as the ducts increased in size (Kolessnikow 1877), while others reported the opposite (Zwart 1911, Nieberle and Cohrs 1931).

The outermost portion of the larger ducts also was found to contain elastic connective tissue and smooth muscle which ran along the ducts in a longitudinal direction (Lund 1931).

**CISTERN OF THE UDDER.** The largest ducts empty into the gland cistern (*sinus lactiferi*, *receptaculum lactis*) whose lining resembles somewhat a netlike cup with recesses, according to Nieberle and Cohrs (1931). Since no secretion took place here, in Rubeli's (1916) opinion, the term epithelial membrane was proposed in place of mucosa by Kamm (1925).

An outer layer of columnar cells and an inner layer of cuboidal cells constituted the epithelial portion of the epithelial membrane (Wirz 1913, Zschokke 1919, Lund 1931, Nieberle and Cohrs 1931, Turner 1933). In older cows the columnar cells manifested a tendency to flatten (Venzke 1940). The epithelium rested on a tunica propria of loose connective tissue and smooth muscle, according to Lund (1931). Within the tunica propria were small glands lined by simple cuboidal epithelium and commonly surrounded by leukocytic infiltrates; these were named accessory glands by Lund (1931) and Venzke (1940).

**TEAT CISTERN AND TEAT.** The teat cistern (*teat sinus*, dilated portion of *ductus papillosus* or *papillaris*, *ductus lactiferi*) was found to be lined by a multilocular membrane (Zwart 1911, Johnston 1938, Rackow 1941, Foust 1941) consisting of double-layered epithelium. The outer cells were columnar and the inner cells cuboidal in character (Wirz 1913, Kamm 1925, Venzke 1940, Foust 1941), although the outer cells tended to be flattened in older cows (Venzke 1940). In some cases it was reported that the epithelium was several layers thick (Kaeppli 1918).

Turner (1933) described the epithelial cells as resting on a basement membrane of wavy tissue in distinction from the deeper tissue which was named tunica propria by Foust (1941) since no muscularis mucosa was seen (Emmerson 1946). Accessory glands were seen in the lamina propria (Riederer 1903, Kamm 1925, Venzke 1940, Emmerson 1946) throughout the length of the teat, although one investigator reported that they were present only at the base of the teat (Kaeppli 1918).

In addition to the mucosal or epithelial membrane, other layers consisted of the muscular, reticular, papillary, dermal, and epidermal layers (Foust 1941).

The muscular layer increased in thickness as it approached the teat apex (Fürstenberg 1868) and consisted of smooth muscle, collagen fibers, elastic tissue, and thick-walled veins and lymphatic vessels often surrounded by leukocytes, according to Foust (1941) and Emmerson (1946). Riederer (1903), Foust (1941) and Emmerson (1946) reported that the muscle was composed of an inner circular layer and an outer longitudinal layer. Kamm (1925) saw some muscle strands directed in an oblique fashion to form netlike trabeculae.

Since no elastic laminae existed in the arteries (Foust 1941) and no valves were found in the veins (Wirz 1913), the two were difficult to differentiate from each other, although one investigator did report he found valves in the veins (Kamm 1925). The fact that the lumina of the arteries were round was considered a helpful differential feature (Turner 1933).

The rich blood supply of the teat led some investigators to consider the tissue as having erectile properties (Fürstenberg 1868, Riederer 1903, Rubeli 1916).

The reticular layer was described as a narrow strip of coarse connective tissue bordering the papillary dermal layer which consisted of delimited papillae projecting into the epidermis (Foust 1941).

Cornified stratified squamous epithelium with sebaceous follicles covered the teat (Fürstenberg 1868). This external epithelium entered the teat canal (constricted ductus papillosus, ductus papillaris, streak canal) and lined the duct (Riederer 1903). Six layers of this epithelium, from outward in, were named by Mankowski (1903) as: 1) Stratum mortificatum; 2) stratum corneum; 3) stratum lucidum; 4) stratum granulosum; 5) stratum spinosum; and 6) stratum germinativum. The first three layers were cornified, the fourth consisted of one or two flattened cells, the fifth was a layer of polygonal cells and the last was a layer of only one cell in depth.

The epithelium covered about five primary longitudinally running folds, each consisting of approximately 10 small secondary folds (Mankowski 1903). These folds rested on a connective tissue ground substance which made deep inroads into the epidermis, the "Marksäulchen" of German authors. The folds themselves consisted of smooth muscle, elastic and connective tissue which began at the teat orifice and thickened in the dorsal direction. The suggestion that the muscle actually formed a network which serves as a mechanism to close the teat canal as a true sphincter was questioned (Fürstenberg 1868).

The dorsal termination of the duct was named Fürstenberg's rosette, an eight-fold structure at which point the stratified squamous epithelium of the teat canal ended abruptly. In this stratified squamous epithelium small sebaceous follicles were reported (Fürstenberg 1868).

*Udder at Time of First Conception.* The virgin udder was found to consist chiefly of fatty tissue traversed by large ducts lined by a double-layered epithelium, and small ducts with a single-layered epithelium. This epithelium rested on a poorly-developed basement membrane which contained a few basket cells. Surrounding the fatty tissue was wavy connective tissue with scattered elastic fibers, smooth muscle cells and leukocytes (Lenfers 1907, Turner 1933, Kwong 1940).



The alveolar ducts in heifers changed with the estrual cycle; at proestrus the ducts and alveoli filled with secretion whereas a week later they were empty. Estrogen was believed to stimulate ductal growth and progesterone to activate parenchymal growth (Turner 1946).

*Changes of Udder During Pregnancy.* Pregnancy caused mitosis, karyokinesis, and epithelial proliferation in the mammary glands of cats, rabbits, and guinea pigs, according to Bizzozero and Vassale (1887). Monthly changes were given by Hammond (1927) as: 1st month—no change; 2nd month—main ducts, minor alveolar ducts with lobuli indistinct, were both lined by a double layer of epithelium; 3rd month—no further change; 4th month—lobuli and interlobular tissue were distinct, small ducts were lined by a single layer of epithelium, and a slight secretion appeared in the alveoli; 5th month—lobuli were well formed, the lobular connective tissue was rich in capillaries, true alveoli were now present and lined by a simple columnar epithelium, secretion was present in the alveoli; 6th month—the alveoli were distended by secretion and the epithelial cells were flattened, the secretion in the alveoli was honey-like; 7th month—the interlobular tissue was thin, and in the alveoli granular-like secretion was forming; 8th and 9th months—no further change. True alveoli appeared at the fifth month of pregnancy. Hammond (1927) believed that no further changes occurred after the 5th month because: a) No further fetal fluids were formed; b) maximum development of the amnionic pustule had occurred; c) formation of cotyledonary attachments was complete.

*Changes During Involution.* Involution has been described as the reverse of development (Trautmann and Fiebiger 1931). It was considered a physiologic process wherein the alveoli lessened in number and grew smaller or disappeared, although a few functional alveoli did persist according to Lenfers (1907). The interlobular and interalveolar tissues increased greatly, *i.e.*, then it underwent mucoid degeneration when the mammary gland prepared for parturition. The process began gradually in small areas involving alveoli and small ducts.

*Cytologic Aspects of Alveolar Epithelium.* An early explanation of milk secretion was offered by Rheinhardt (1847) who suggested that the alveolar epithelium sloughed off. Another approach suggested that the alveolar epithelium actually underwent fatty degeneration (Fürstenberg 1868, Kehrer 1871). The leukocyte was considered at one time as the parenchymatous cell and the function of the alveoli was merely that of a storage mechanism, according to Rauber (1879). The present concept of milk production, namely, that the cells remain intact and continue to produce milk, apparently was first expressed by Langer (1871). The decapitation theory (Heidenhain 1883) arose later but has given way to the apocrine theory (Brouha 1905).

*Colostrum Corpuscle.* The colostrum body was described as a small irregular granulated body containing a nucleus and probably not concerned with milk production (Rheinhardt 1847). Sloughed-off epithelial cells (Rheinhardt 1847, Lenfers 1907) and leukocytes (Maximow and Bloom 1938) have been suggested as the origin of these bodies. Czerny (1890) felt that colostrum bodies were leukocytes which phagocytized unused milk.

*Corpus Amylaceum.* Corpora amylacea were described by Ottolenghi (1901) as varied sized concretions (30 to 250 microns) consisting of stratified layers and as resistant to acids, alkalis and fat solvents. These bodies were seen in the alveolar lumen, the alveolar epithelium, and the interstitium by Zimmermann (1909), Joest and Steck (1924). It was suggested that corpora amylacea formed in the alveoli and that fibrosis consequent to mastitis caused them to become interstitial in location (Morrill 1938). While Morrill (1938) reported their increase in relation to the length of lactation, Zimmermann (1909), Nieberle and Cohrs (1931) saw no relation to length of lactation or age. Their origin was not necessarily the same in each instance. One form was considerably smaller than epithelial cells and was thought to start as a free alveolar body which was built up by precipitation of mineral salts, whereas another form started around a free epithelial cell, according to McFadyean (1930).

*Supramammary Lymph Nodes.* Baum (1912) found the number of lymph nodes varying from one to six for the whole udder. Their size was found to vary considerably and was given as: Ellenberger and Baum (1915) 2 to 10 by 1 to 3 by  $\frac{1}{4}$  to 1 cms.; Sisson (1914) 6 to 10 cms. long; Emmerson (1928) 3 to 9 by 3 to 6 by 1 to 2 cms.; Staack (1933) 5 to 15 by 3 to 6 by 1 to 2 cms.; Kitt (1931) almond sized.

### Histopathologic Changes in the Udder

*Historical Considerations.* Leblanc (1901) credited de Brassac (1814) as one of the earliest to write on mastitis, and Munch-Peterson (1938) recognized Vatel (1828) as an early author on the pathology of mastitis. In that period the disease was referred to as "gelber Galt," although it appeared that this term was particularly employed for what is now known as streptococcic mastitis. The origin and translation of "gelber Galt" could not be determined. The earliest reference found was by Rast (1854).

Kitt (1886) referred to previous pathologic treatises of bovine mastitis by Fürstenberg (1868), Gerlack, Götze, Hartmann, Kotelmann, and Schlösser (1883). Kitt (1886) gave no bibliographic notes or references to their respective works, hence such papers are difficult to locate.

In 1868 Fürstenberg (1868) published a book on the bovine udder and its diseases. This was a comprehensive study but it failed to consider the bacteriology of bovine mastitis as it antedated that science. A few years later, Franck (1876) and Kitt (1882) demonstrated the transmissible properties of the disease by causing the condition to appear in healthy quarters when injected with material from involved quarters. Nocard and Mollereau (1885) isolated a streptococcus from a case of mastitis and reproduced the disease in a healthy udder by injecting the organism.

Schlösser (1883) reported on a biopsy technique which procedure has since been developed to a higher degree by Andberg *et al.* (1942), (1943). In addition he advanced the theory that all phases of the disease could be seen in a single udder.

Bovine mastitis was compared with other pathologic conditions such as pneumonia by Zobel (1902) and dermatitis by Diernhofer (1929). Zobel (1902) noted that involution resulted in histologic changes resembling mastitis, a fact later confirmed by Lubke (1934) and Olafson (1948).

*Classification of Mastitis.* Most authors presented classifications which were original with them with the result that homologizing the various concepts was difficult and often confusing. A partial list of classifications was compiled as follows:

Fürstenberg (1868)	<ol style="list-style-type: none"> <li>1. Hyperemic mastitis*</li> <li>2. Inflammatory mastitis*</li> <li>3. New growths*</li> </ol>
Schlösser (1883)	<ol style="list-style-type: none"> <li>1. Acute mastitis*</li> <li>2. Chronic mastitis*</li> </ol>
Kitt (1886)	<ol style="list-style-type: none"> <li>1. Noninfectious inflammatory edematous mastitis*</li> <li>2. Infectious inflammatory edematous mastitis*</li> <li>3. Catarrhal sporadic mastitis*</li> <li>4. Catarrhal sporadic infectious mastitis*</li> </ol>
Leblanc (1901)	<ol style="list-style-type: none"> <li>1. Acute mastitis, catarrhal and parenchymatous*</li> <li>2. Chronic mastitis*</li> </ol>
Zobel (1902)	<ol style="list-style-type: none"> <li>1. Acute mastitis*</li> <li>2. Chronic mastitis*</li> </ol>
Frei (1925)	<ol style="list-style-type: none"> <li>1. Mastitis simplex</li> <li>2. Mastitis apostematosa</li> <li>3. Mastitis necrotica</li> <li>4. Mastitis indurativa</li> </ol>
Lund (1931)	<ol style="list-style-type: none"> <li>1. Thelitis</li> <li>2. Galactophoritis</li> <li>3. Mastitis simplex</li> <li>4. Mastitis apostematosa</li> <li>5. Mastitis necrotica</li> <li>6. Mastitis indurativa</li> </ol>
Sholl and Torrey (1931)	<ol style="list-style-type: none"> <li>1. Interstitial mastitis</li> <li>2. Exudative mastitis</li> <li>3. Suppurative mastitis</li> <li>4. Fibrosis</li> </ol>
Nieberle and Cohrs (1931)	<ol style="list-style-type: none"> <li>1. Nonspecific diffuse mastitis*</li> <li>2. Necrotic mastitis*</li> <li>3. Gelber Galt</li> <li>4. Pyogenic mastitis*</li> </ol>
Seifried (1934)	<ol style="list-style-type: none"> <li>1. Acute mastitis*</li> <li>2. Chronic mastitis*</li> </ol>
Gibbons (1938)	<ol style="list-style-type: none"> <li>1. Thelitis</li> <li>2. Acute catarrhal galactophoritis</li> <li>3. Acute parenchymatous mastitis</li> <li>4. Acute purulent mastitis</li> <li>5. Gangrenous mastitis</li> <li>6. Chronic productive mastitis</li> </ol>

\* Translated

Runnells (1946)	<ol style="list-style-type: none"> <li>1. Acute diffuse mastitis</li> <li>2. Chronic diffuse mastitis</li> <li>3. Subacute and chronic focal mastitis</li> <li>4. Suppurative mastitis</li> </ol>
Sholl (1946)	<ol style="list-style-type: none"> <li>1. Interstitial mastitis</li> <li>2. Exudative mastitis</li> <li>3. Suppurative mastitis</li> <li>4. Gangrene mastitis</li> <li>5. Fibrosis</li> </ol>
Chu (1949)	<ol style="list-style-type: none"> <li>1. Acute suppurative mastitis</li> <li>2. Acute catarrhal mastitis</li> <li>3. Subacute suppurative mastitis</li> <li>4. Subacute catarrhal mastitis</li> <li>5. Chronic mastitis</li> </ol>
Spencer (1949)	<ol style="list-style-type: none"> <li>1. Acute mastitis</li> <li>2. Chronic mastitis</li> </ol>

From this outline it can be seen that Gibbons (1938) adopted Frei's (1925) and Lund's (1931) classification. Schlösser (1883) initiated the simple classification into acute or chronic which was most recently employed by Spencer (1949). The latter author made the point that mastitis was best classified as acute or chronic and that the other terms such as exudative, and so forth, properly belonged in the realm of descriptive morphology.

Leblanc (1901), Nieberle and Cohrs (1931), and Runnells (1946) pointed out that the terms "interstitial" and "parenchymatous" were obsolete in that mastitis did not confine itself to either tissue for any appreciable time.

*Acute Mastitis.* Acute mastitis was chiefly an exudative inflammation of the cistern, the ducts and the alveoli, according to Seifried (1934). The alveoli usually contained a serous material with cells which were essentially heterophils, some macrophages and groups of plasma cells, together with desquamated epithelium. The fluid content of the alveoli was homogenous, the alveolar epithelium markedly vacuolated, and the cells often appeared as a stringy mass. The interalveolar tissue may be markedly infiltrated by histiocytes. Schlösser (1883), Mathis (1885) and Lucet (1889) recognized that the alveoli were involved in the acute form, becoming distended with pus while the epithelium underwent desquamation or degeneration. Lucet (1889) noted that in addition to leukocytes within the alveoli there often were erythrocytes which were accompanied by a purulent disintegration of the alveolar wall itself, often leading to abscess formation, in the opinion of Leblanc (1901).

Zobel (1902) wrote a fairly detailed report. He found the alveoli and ductal lumina were clogged by cellular debris consisting of sloughed epithelial cells, bacterial rods and cocci, blood, fibrin, and leukocytes. (The older Germanic writers apparently used leukocyte to describe heterophils, and round cell to describe lymphocytes.) The epithelial cells appeared to be more vacuolated than usual, while other cells showed chromatinolysis and fragmentation. Leukocytes were prominently scattered among



the alveolar epithelium. The interalveolar tissue presented single leukocytes and was thickened owing to serous infiltration; a few of the interalveolar blood vessels contained thrombi. Schlösser (1883) however, noted that the interalveolar tissue was often markedly infiltrated by lymphocytes.

Franck (1876), Guillebeau (1890), and Hess (1911) reported that bacteria were visible in the interalveolar tissue, but Zobel (1902) could not duplicate their findings and expressed the opinion that his staining techniques were at fault. Frei (1925) and Lund (1931) agreed with Zobel (1902) on essential points, but used the words mastitis simplex to describe acute mastitis. Frei (1925) employed the term mastitis apostematosa when mastitis simplex had extended to the ducts and showed leukocytic infiltration and hypertrophy of the mucosa; this form may become chronic and result in abscess formation and fibrosis.

Lund (1931) agreed that mastitis apostematosa was an extension of mastitis simplex, but that it was essentially an abscess-forming process. This latter process was designated by Gibbons (1938) and Sholl (1946) as purulent or acute suppurative mastitis or as a chronic abscess-forming condition respectively, while Nieberle and Cohrs (1931) called it pyogenic mastitis or Holstein udder disease. Chu (1949) appeared to agree with Frei's (1925) and Gibbons' (1938) designation of acute suppurative mastitis because it was not a chronic disease but one characterized by pus, heterophils, degeneration, and desquamation of alveolar epithelium and possibly by slight interstitial fibrosis. Another condition that was similar, except for the lack of suppuration, was designated by Chu (1949) as acute catarrhal mastitis. Thus Lund (1931), Nieberle and Cohrs (1931), Runnells (1946), and Sholl (1946) used the term suppurative mastitis only in connection with chronic mastitis.

With further reference to Frei's (1925) and Lund's (1931) mastitis simplex, both authors agreed that the interstitium was only slightly involved, there being leukocytic and lymphocytic infiltration with edema. Frei (1925) pointed out that the involvement was not necessarily in proportion to the epithelial changes. Nieberle and Cohrs (1931) saw no reason to differentiate between mastitis simplex and mastitis apostematosa as they believed ductal or parenchymal infection *per se* to be only theoretical. They stated that the infection did not confine itself very long to any one tissue. Lund (1931) and Gibbons (1938) even mentioned such forms of mastitis as thelitis and galactophoritis, although they admitted these conditions changed within a short period to either mastitis simplex or to recovery.

Three variations of acute mastitis under the heading of nonspecific diffuse mastitis, in addition to pyogenic mastitis, were listed by Nieberle and Cohrs (1931). First they described serous inflammation in which there was a pronounced inflammatory edema of the interstitium, dilated lymph ducts, and leukocytic and histiocytic aggregates in the interstitium. The inflammatory cells were apt to invade the ducts and alveolar lumina and to cause sloughing of the epithelium. Fürstenberg (1868) described similar phenomena under the term hyperemic mastitis which he subdivided into two forms. The first form corresponded to parturient edema which was characterized by dilated blood vessels and lymph spaces of the interstitium; the second form was caused by trauma, heat, or cold, reflecting the serous inflammation of Nieberle and Cohrs (1931).

The second variation described by Nieberle and Cohrs (1931) was characterized by the predominance of exudative cells over edema. The third form or hemorrhagic inflammation was characterized by diapedesis of erythrocytes. In more detail, they saw a sero-hemorrhagic-exudative inflammation in the alveoli and interalveolar tissue, the cellular components being chiefly leukocytes and histiocytes. Runnells' (1946) description of acute diffuse mastitis agreed on the essential points with that of Nieberle and Cohrs (1931). Sholl (1946) described acute mastitis under the heading of acute exudative mastitis and characterized by cellular exudate in the alveoli and ducts, accompanied by degenerative and necrotic changes in the parenchyma. The intensity of the pathologic process varied widely from a few heterophils within an alveolus to solidly-packed cells, accompanied by degeneration and desquamation and even necrosis.

*Necrotic Mastitis.* Relatively few authors described this condition. Zobel (1902) devoted a section of his paper to udder necrosis, namely to the formation of encapsulated sequesters. There existed a sharp delineation between the normal and abnormal parenchyma, the latter staining pale. Leukocytes and epithelial cells were recognized within the affected area. Outside of the necrotic area practically all phases of parenchymatous mastitis could be observed; this later term apparently was used by Zobel (1902) to indicate acute mastitis.

The term mastitis necrotica was applied by Frei (1925) to a complete destruction of all involved tissues and he subdivided it into a wet and dry form.

The dry form was localized, perhaps caused by a thrombus, often sterile, and encircled by leukocytes. The center was usually completely necrotic. Lund (1931) also mentioned, under mastitis necrotica, the occurrence of dry sequesters that were well encapsulated by fibrous tissue and surrounded by a zone of leukocytes.

The wet form, according to Frei (1925), was characterized by liquefaction necrosis or complete destruction of the involved tissue by infiltrates with leukocytes, fibroblasts, fibrin, and collateral edema over a wide area. Lund (1931) added that bacteria may be seen within the tissues involved. Necrotic mastitis was found to be more common in sheep than in cows, but was described as a widespread necrosis by Nieberle and Cohrs (1931); there was extensive alveolar epithelial death, infiltration of leukocytes, loss of architecture, extensive thrombosis of lymph and blood vessels with many perivascular lymphocytic cuffs. At times the authors noted an inclination of the process to localize. Sholl (1946) saw the condition as an extensive necrosis of all areas involved.

*Suppurative Mastitis.* Several writers have included this term in their classification of mastitis. Not all of them employed it in the same sense. Those who used suppurative mastitis to indicate an acute condition were mentioned in connection with the review of acute mastitis.

Suppurative mastitis was an extension of mastitis simplex according to Lund (1931). The initial stages consisted of focal masses of heterophils. Soon a capsule formed, richly infiltrated with lymphocytes and leukocytes. Bacteria often were visible. Perifocal areas either were normal or were characterized by desquamation of the alveolar epithelium. Nieberle and Cohrs (1931) called this type "pyogenic mastitis" (Holstein udder disease) and found it usually in pastured animals; this probably has led to the

name, "summer mastitis." Grossly, this disease was characterized by varied-sized abscesses resembling those elsewhere in the body. Often it was seen in ducts from where it extended to other parts of the udder. There was a marked leukocytic exudate within the ducts with destruction of the ductal epithelium and fibrous material replacing the desquamated epithelium. The alveoli contained various stages of epithelial changes and leukocytic infiltration. Abscesses of microscopic size were seen within the interstitium.

In conclusion, Nieberle and Cohrs (1931) defined this disease as a pure exudative mastitis with strong productive tendencies. Runnells (1946) agreed quite well with Nieberle and Cohr's description and added that the abscess capsule at times appeared to be two-layered, showing a direct relationship to the affected lactiferous ducts. Sholl's (1946) concise description was that suppurative mastitis was characterized by necrosis, purulent exudate, connective tissue, proliferation, and encapsulation.

*Chronic Mastitis.* Fürstenberg (1868) was well aware of this form which he described as a connective tissue proliferation accompanied by loss of parenchyma. The same observation was made by Schlösser (1883), who felt that every form of mastitis was primarily interstitial in character with alveoli involved secondarily. Seifried's (1934) definition indicated a condition in which the alveoli and the small ducts atrophied with a consequent increase of interalveolar connective tissue, resulting in so-called fibrosis. Lund (1931) and Gibbons (1938) called fibrosis the prominent feature of chronic mastitis. Frei (1925), Lund (1931), Gibbons (1938) and Sholl (1946) agreed that chronic mastitis was often a sequel to acute mastitis. Runnells (1946) stated that it was an atrophic process, with fibrosis of the parenchyma beginning as an exudative suppurative inflammation of the lactiferous sinus, a condition which later became chronic. Frei (1925) noted that the alveoli were empty or contained leukocytes in the lumina, the epithelium being absent or consisting of high cylindrical elements with scanty cytoplasm and large nuclei. Lund (1931) described the alveolar epithelium as flattened. Frei (1925) said that colostrum bodies did occur and that corpora amylacea were common.

The increase of the interstitium was of variable intensity, the greatest increase being seen about the large ducts, according to Gibbons (1938). Lund (1931) and Gibbons (1938) saw lymphocytes and sometimes heterophils infiltrating the interstitium. There was proliferation in the mucosa of the cistern and of the ducts, nodules of large mononuclears, plasma cells, and fibroblasts which also appeared in the interalveolar tissue in the region of the affected ducts, according to Runnells (1946). Sholl (1946) found that fibrosis could progress to the point where one-half of the observed section represented connective tissue, while here and there active alveoli could be found.

### Specific Mastitides

*Brucellosis Mastitis.* Brucellosis could cause a change in the bovine udder as indicated by a definite increase in the leukocyte count of the milk, according to Cooledge (1916) and Tweed (1923). Bryan and Meyer (1936) examined milk by leukocyte count, methylene blue reduction, and pH tests, and concluded that brucellosis could cause a low-

grade mastitis. On the other hand, Emminger and Schalm (1943) did not believe that the milk was changed significantly.

No gross lesions were seen in the one udder which Friedemann (1922) studied. Fitch and Bishop (1934) believed that clinical mastitis was rare in brucellosis. The single case of Friedemann (1922) failed to reveal histological lesions. Runnells and Huddleson (1925) studied the problem in four cases from which they obtained the organism in pure culture. They reported that the pathologic process was progressive in character, first attacking the parenchyma and then the interstitium; lesions were present in the alveoli, the interalveolar tissue and in the lactiferous ducts but without visible bacteria.

The lesions displayed considerable variability. The minimal alteration was represented by interstitial lymphocytic infiltration. More definite changes consisted of heterophils, desquamated epithelial cells, corpora amylacea, granular masses, and mononuclear cells within the ductal and alveolar lumina. Pedersen (1933) found many erythrocytes in some of his cases, whereas Emminger and Schalm (1943) reported epithelioid and giant cells. According to Runnells and Huddleson (1925), epithelial changes were represented by fatty degeneration, necrosis, disintegration, and desquamation, similar to the reports of Pedersen (1933), Lübke (1934), and Emminger and Schalm (1943). Some evidence for epithelial proliferation was suggested by Hofstad (1942). The interalveolar tissue may be moderately increased according to Runnells and Huddleson (1925) which change became intensified as the process continued on to chronicity. In this latter stage fibroblasts proliferated, and heterophils, lymphocytes, plasma cells, eosinophils and polyblasts appeared. Hofstad (1942) believed the lesions to be primarily in the interalveolar tissue as evidenced by mononuclear foci with few heterophils and eosinophils. Lübke (1934), and Runnells and Huddleson (1925) attributed the loss of alveoli to an increase of interalveolar tissue. Congestion and edema of the interlobular tissue were seen by Runnells and Huddleson (1925), which observation was confirmed by Hofstad (1942) to the extent that this tissue was increased in amount. According to Runnells and Huddleson (1925) the subepithelial areas of the larger ducts were infiltrated by the so-called periductal lymphocytic infiltrates, Pedersen (1933).

Reporting on brucellosis mastitis, Smith *et al.* (1923) described lesions similar to the above. In addition to the brucella organism the authors also isolated a beta-hemolytic streptococcus. Munch-Petersen (1935) quoted Gill (1933) as believing that *Brucella abortus* paved the way for streptococcal infections.

*Leptospiral Mastitis.* Jungherr (1944) first described bovine leptospirosis in the United States and noted a bloody milk secretion. A similar observation was made by Little *et al.* (1950), Little and Baker (1950), and Spencer and Lillesand (1950). The last two papers brought out the points that the udder was soft and flabby and without apparent tissue changes.

*Staphylococcic Mastitis.* Histologic descriptions of staphylococcic mastitis were rather sparse in the literature. Palmer *et al.* (1941) described mastitis in heifers which was believed to have been caused by staphylococci. They saw a pronounced fibrosis. At times the lactiferous sinuses and ducts were completely obliterated by proliferating connective tissue. Heterophils infiltrated the involved areas. Some of their cases actually developed gangrene. Sholl and Torrey (1931) found staphylococci in some of their



cases and described an interstitial fibrosis in connection with this type of mastitis. On the other hand, Pedersen (1933) saw no changes in field cases and only thickened milk for eight days in an experimental case.

*Streptococcic Mastitis.* Because many of the papers were written prior to the modern differentiation of bovine streptococci, this portion of the review considered all types of streptococcic mastitides.

Diernhofer (1929) pointed out that there were two types of streptococcic mastitis, namely, one nonspecific, subacute to chronic, and self-healing, and another type that was chronic, contagious and caused by a specific or definite streptococcus. Zschokke and Strebel (1897) stated that "gelber Galt" was a disease of the alveolar and ductal epithelium and not of the stroma.

Stark (1903), Van der Linde (1906), Himstedt (1927), Diernhofer (1929), Hemmert-Halswick (1933), Gonzales Alvarez (1935), and Chu (1949) appeared to agree that the disease was one of the alveolar lumina and of the ducts. All authors used such words as "catarrhal" and "parenchymal" in their descriptions. Stark (1903), Van der Linde (1906), and Hemmert-Halswick (1933) likened streptococci mastitis to pneumonia and believed it to be a disease of the lumina. Ibel (1904) felt that the stroma was first involved and then the alveoli; he offered as evidence the fact that leukocytes were seen in great numbers in the stroma early in the disease. Ohlen (1934) infected different quarters of the same cow at weekly intervals with an organism designated by him as "diplokokk" in the Swedish language. According to Jorgensen (1950) this organism was a streptococcus. At any rate, Ohlen (1934) slaughtered the cow within 24 hours after the last injection and found many leukocytes, enlarged alveoli, desquamated epithelium, and interalveolar edema.

"Gelber Galt" was an acute disease which rapidly progressed to an inactive or terminal phase, according to Ibel (1904). Stark (1903), Himstedt (1927), Hemmert-Halswick (1933), Sholl (1946), and Chu (1949) classified streptococcic mastitis as both acute and chronic, believing the acute stage to progress to the chronic one. Morrill's (1938) concept was that streptococcic mastitis was a chronic progressive disease that was associated with some areas of acute exudative inflammation.

Streptococcic mastitis was early described from the microscopic point of view by Hess and Borgeaud (1888). They noted that the ductal and alveolar lumina contain epithelial sloughs and giant cells, although Ibel (1904) never could see these giant cells. Faber and Rottenstein (1934) have described these cells in humans, and Emminger and Schalm (1943) in bovine brucellosis mastitis. Faber and Rottenstein (1934) recognized two types of giant cells, namely, one formed by fusion of epithelial cells, and the other by phagocytic action of endothelial cells. Ernst (1909) saw colostrum bodies and corpora amylacea in the lumina, with Jorgensen (1924) adding fibrinous exudate in beta-hemolytic streptococcus infections.

Common elements found within the lumina were heterophils according to Ibel (1904), Van der Linde (1906), Hess (1911), Jorgensen (1924), Himstedt (1927), Hemmert-Halswick (1933), and Lohse (1933). However, Gonzales Alvarez (1935) believed that lymphocytes were the most common component in the exudate along with plasma cells, to which he accorded diagnostic significance in streptococcic mastitis. Plasma cells and lymphocytes within the lumina were reported by Lohse (1933). Hadwen and Gwatkin (1939) worked with milk smears and concluded that mono-

nuclear elements tended to be present in greater numbers than heterophils in streptococcic mastitis than in staphylococcic mastitis.

Organisms within udders affected by streptococcic mastitis have been reported by many investigators. Hess and Borgeaud (1888), Stark (1903), Hess (1911), Himstedt (1927), Diernhofer (1929), Stradtman (1931), Hemmert-Halswick (1933), and Lohse (1933) observed streptococci within the ductal and alveolar lumina. Himstedt (1927), Stradtman (1931), Hemmert-Halswick (1933), and Lohse (1933) saw bacteria infrequently within the alveolar tissue and Diernhofer (1929) said that organisms were common within the tissue even in dry cows.

The tubular and alveolar epithelia were described by Stark (1903) as loose and desquamated in some areas. The cells were vacuolated. Morrill (1938) called this condition vacuolar degeneration since the vacuoles did not always take the fat stain, although Hemmert-Halswick (1932) had designated the changes as fatty degeneration. Jorgensen (1942) noted necrosis, pyknosis, and karyorrhexis.

Epithelial hyperplasia with polyp formation was seen by Van der Linde (1906), particularly in the cistern and large ducts. Stark (1903), Hess (1911), and Hemmert-Halswick (1933) noted in gross examination that the cisternal mucosa was rough, which condition Lohse (1933) ascribed to papillae of hyperplastic epithelium. These nodules were the result of dilated capillaries and of fibrosis and caused niches that enclosed bacteria and cellular debris according to Stark (1903). Johnston (1938) found such niches, which form normally, to be capable of retaining small carbon particles and probably also bacteria. Murphy (1945) described exaggerated folds in the cisternal mucosa, which Spencer (1949) interpreted as epithelial hyperplastic areas.

In the early stages of streptococcic mastitis the alveoli were enlarged, then were subject to degeneration as suggested by Van der Linde (1906) and Hemmert-Halswick (1933), although Morrill (1938) and Sholl (1946) found them fairly resistant. All of the investigators cited agreed that there was an interalveolar increase of connective tissue and a subsequent alveolar decrease. The alveoli may become completely lost as Hess (1911) observed, or collapsed to appear as tubules as seen by Ibel (1904). This interalveolar increase was considered to be an embryologic reversion by Lohse (1933), whereas Hemmert-Halswick (1933) declared it to be true granulation tissue. Interalveolar hemorrhages were reported by Hess and Borgeaud (1888).

Leukocytes within the interalveolar tissue were reported by most investigators. The lymphocyte was the most common cell, then the heterophil, and then the other various leukocytes and histogenous phagocytes. For simplification, a tabular form is employed to illustrate the various authors' results. (See page 19).

Streptococcic mastitides most frequently caused the pathologic changes to appear in the ventral portions of the udder according to Miller (1936), Morrill (1938), and Spencer (1949).

*Viral Mastitis.* Broadhurst *et al.* (1939) reported that they had succeeded in isolating a virus from the blood and milk of cows infected with clinical mastitis. This agent produced mastitis in mice. Bushnell (1942) attempted to isolate viruses from mastitic cows but was not successful. Peterson *et al.* (1938) rendered a histologic description of a form of mastitis in which the milk failed to yield recoverable pathogens. They believed the cases to be of viral origin. The lesions were described as presenting a rather

sharp line of demarcation between normal and abnormal udder tissue, alveoli decreasing in size, alveolar epithelium cytolyzed, and lymphocytes infiltrating the subepithelial tissue. Few eosinophils were present and heterophils were uncommon. The stroma exhibited increased fibroblasts, plasma cells, and macrophages.

Little (1946) commented in his report that a virus-like agent has been recovered from guinea pigs which were inoculated with bloody milk from lactating cows. He decided against the disease being of viral etiology and ascribed it to a specific spirochete.

*Cryptococcal Mastitis.* This is a relatively newly-recognized form of mastitis (Pounden *et al.* 1952) and few reports exist. Innes *et al.* (1952) reported that the histologic picture was characterized by dissolution of the alveolar and ductal epithelium. Large numbers of *Cryptococcus neoformans* were seen in the glandular lumina, in the sinusoids of the supramammary lymph nodes and one in the lung. At times the organisms and the skeleton of the basement membrane and interlobular fibrous network were all that remained of the parenchyma.

*Mycobacterial Mastitis.* This type was recently reported by Tucker *et al.* (1953). A mycobacterium was isolated from the milk secretion of infected cows but no specific name had been assigned to the organism at the time of the report. The disease was characterized by marked hypertrophy of the involved quarters. Varied-sized granulomata were seen throughout the mammary tissue.

#### *Types of leukocytes in interalveolar tissue according to the literature*

AUTHOR	Eosinophils	Heterophils	Histiocytes	Lymphocytes	Mast Cells	Monocytes	Plasma Cells	Reticulo-Endothelial Cells	Leukocytes Not differentiated
Stark (1903)		x		x					
Ibel (1904)									x
Ernst (1909)				x					
Himstedt (1927)	x			x					
Hemmert-Halswick (1933)		x							
Lohse (1933)	x	x	x	x			x		
Ohlen (1934)		x		x					
Gonzales Alvarez (1935)					x		x		
Morrill (1938)			x	x					
Sholl (1946)		x		x			x	x	
Chu (1949)	x		x	x					
Spencer (1949)				x		x	x		

## The Supramammary Lymph Node in Mastitis

In acute mastitis the lymph nodes become only slightly edematous, according to Zobel (1902). In cases of necrotic mastitis, the only other change may be an occasional necrotic focus. Frei (1925) considered lymph node changes to be nonexistent in mild cases, whereas in severe or prolonged cases there may be an enlargement of the lymph node to fist-size.

In streptococcic mastitis Ernst (1909) described enlarged fist-sized, whitish-gray nodes, as did Hess (1911). Staack (1933) wrote an entire dissertation on the lymph nodes in streptococcic mastitis, his paper being by far the most detailed one on the subject. The central theme of his dissertation was that the lymph nodes reflected the condition of the udder, thus, fibrosis of the udder resulted in sclerosis of the node. Staack (1933) divided the lymph node changes into three groups:

GROUP A—Udder undergoing acute to subacute mastitis with an inflammatory exudate. The nodes were swollen, lymphatic tissue was hyperplastic, and the sinuses were markedly dilated and filled with proliferated endothelial cells and leukocytes. A typical sinus catarrh existed with some areas of pus in the medulla.

GROUP B—Udder undergoing subacute to chronic mastitis, characterized by marked exudation in the parenchyma. The nodes were not particularly swollen, nor were the sinuses dilated. There was induration in the medulla and proliferation of reticulo-endothelial cells in the trabeculae.

GROUP C—Udder undergoing chronic productive mastitis. The nodes were atrophied. Marked fibrosis and induration in the medulla extending to the cortex, were seen.

Histologic examination of lymph nodes of streptococcic mastitis cases usually revealed only slight changes (Stark 1903). These consisted of occasional foci of heterophils and moderate edema with no apparent disruption of the architecture. Streptococci were reported as existing in the nodes by Hemmert-Halswick (1933); however, the characteristic chain formation was lacking as only individual cocci were observed.

*Brucella* mastitis was reported as capable of causing lymph-node changes in the cortex such as septal thickening and an increase of germinal centers with some of them containing hyaline masses. In the medulla the reticular fibers were replaced by fibrous connective tissue, with only a few islands of lymphoid tissue remaining (Runnells and Huddleson 1925). As a result of bacterial toxins produced in the udder and taken up by the lymph, the reticulo-endothelial cells underwent necrobiosis (Lübke 1934). Hemorrhages and hyperemia also were reported by Emminger and Schalm (1943).

## Leukocytes in Udder and Milk

Leukocytes were reported as commonly found in the alveolar epithelium and the interalveolar tissue of normal animals, according to Lenfers (1907). In this particular work no mention was made of bacteriological



studies. Leukocytes were seen in the alveolar lumina, particularly in early lactation, by Zwart (1911), but another report stated that they were common in late lactation (Nieberle and Cohrs 1931) since their duty was to phagocytize the remaining secretion (Trautmann and Fiebiger 1931). Leukocytes in late lactation were likewise found to be prevalent in the interalveolar tissue from whence they entered the lumina; these leukocytes became laden with fat and changed into colostrum bodies, according to Nieberle and Cohrs (1931). This latter condition occurred chiefly in early lactation.

One type of leukocyte, namely the lymphocyte, appeared to be a normal constituent of interalveolar tissue and was regarded as not necessarily of pathologic significance by Chu (1948). However, the presence of heterophils was considered to indicate an inflammatory process (Maximow and Bloom 1938). The heterophil was regarded as the chief phagocytic cell (Hadwen 1941).

The significance of leukocytes in milk smears has been the subject of much discussion. From the pathologist's viewpoint, significant numbers varied from none to millions, although it has been stated that 20,000 leukocytes per millimeter should be the maximum in milk from a normal healthy udder (Chu 1949). The proportions of the various leukocytes in smears showed the following relationship: In staphylococcic mastitis, heterophils have been reported as predominant, whereas in streptococcic mastitis, mononuclear forms were considered to be characteristic (Hadwen and Gwatkin 1939). Adler and Migaki (1951) considered an increase of heterophils as indicative of staphylococcic infection.

Finally, the question was raised as to whether leukocytes were actually leukocytes or merely epithelial cells whose morphology has been altered so as to resemble leukocytes (Hopkirk 1933, Duran-Jorda 1944).

### Pathogenesis

Few investigators have considered this phase of mastitis. However, Spencer (1949) devoted an entire thesis to this problem, his work being by far the most informative one.

Kitt (1886) believed that the infectious agents spread in a number of ways but principally by the lymphogenous and hematogenous routes. Kitt (1886) also considered spread to occur along the ducts, while Stark (1903) thought that the heterophils actually carried the organisms and were responsible for new foci of infection. He visualized spread to take place by way of blood and lymph system, as well as by ducts; the vascular spread was confined to the udder. Mastitic streptococci were injected parenterally with no results by Reinhoff (1929), Maas (1932), Schlegel (1933), and Hopkirk (1935). Christiansen and Nielsen (1934), however, injected large amounts of streptococci (10 to 30 mls) into the mammary artery and did produce some mastitis. Stradtman (1931) believed that a pyogenic bacterium was necessary to pave the way for an invasion of streptococci. Gill (1933) claimed that *Brucella abortus* in the udder predisposed this organ to streptococcic mastitis.

Spencer (1949) discussed the pathogenesis of acute and chronic streptococcic mastitis. In the acute form he stated that the organism spread along the duct system, the medium and small ducts becoming occluded with fibrin, leukocytes, and organisms. The alveoli became distended and the epithelium vacuolated; the alveoli then began to decrease in size

as a result of interstitial edema. He pointed out that damming of the flow of secretion by edema and clots of exudate encouraged the spread and multiplication of organisms and thus furthered the infection. Acute mastitis resulted in a watery discharge which in two or three days contained clots of exudate, evidence of regression of the acute process. The removal of the clots promoted drainage and thus aided recovery.

In the case of chronic streptococcic mastitis, Spencer (1949) saw scattered foci of inflammation as probably related to a partial or complete blocking of small ducts by fibrin clots. The process apparently had existed for some time as some foci were made up merely of heterophils, whereas other foci were representative of fibrosis and atrophy. Since foci of acute inflammation were observed in most quarters with chronic streptococcic mastitis, Spencer (1949) concluded that the development of lesions was a periodic extension to new areas as the old areas underwent regression. Spencer (1949) disagreed with Murphy's (1945) triphasal concept, namely, invasion, infection, and inflammation. Spencer believed that inflammation could be found within two weeks of infection, and that acute inflammatory lesions of short duration were similar to those of many months duration.

The pathogenetic process of streptococcic mastitis was an extremely short one in the view of Ohlen (1934). Within 24 hours after injection of a culture, there existed a well-developed mastitis of the so-called acute form. Spencer (1949) believed that the step from invasion to inflammation was probably only a matter of hours.

Another point raised by Spencer (1949) was the possible existence of hypersensitivity to streptococci so that relatively few organisms could cause a severe reaction. Diernhofer (1929) stated that streptococci were almost saprophytic in their host relation. The folds of the cisternal mucosa which Spencer (1949) interpreted as epithelial hyperplasia were considered by Murphy (1945) as unrelated to the incidence of mastitis, whereas Johnston (1938) and Spencer (1949) accorded them a role in the pathogenesis by retaining both organisms and milk and thus creating a favorable environment for bacteria.

## MATERIALS AND METHODS

This study was based upon bacteriologic and pathologic data on bovine udders, collected by Plastringe and Jungherr, respectively, during the period from November 1930 to November 1950. A total of 138 udders were available for histologic study, 130 of which were from the University of Connecticut herd, free from brucellosis since 1924. The remaining eight udders came from nearby abattoirs and farms.

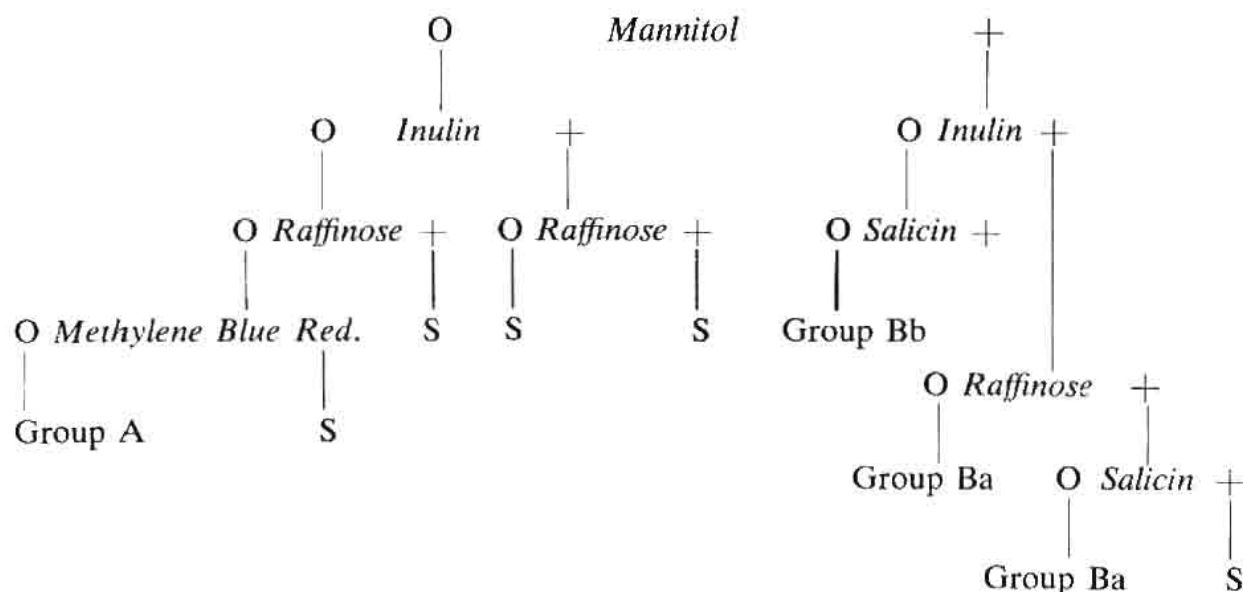
The technique of bacteriologic examination of the milk varied down through the years. For the period up to 1934 the method of Plastringe *et al.* (1934) was employed. Milk samples were drawn aseptically after discarding four streams. Blood agar was inoculated by placing 1 ml. of 1:10 dilution of the sample in a Petri dish and adding 10 ml. of melted nutrient agar containing 0.5 percent NaCl and 5 percent defibrinated bovine blood. The plates were examined after 48 hours at 37°C, and colonies were picked for further identification. Colonies of organisms suspected as being streptococci, staphylococci, coliforms, corynebacteria, and so forth were subjected to routine bacteriologic methods for identification. Streptococci

were further identified by picking the colonies and inoculating them into blood broth; 0.1 ml amounts of the 24-hour blood broth cultures were inoculated into methylene blue milk 1:5,000, litmus milk, aesculin broth, sodium hippurate broth, and serum-carbohydrate broths. The carbohydrates used were dextrose, galactose, lactose, levulose, maltose, sucrose, mannose, raffinose, arabinose, xylose, trehalose, salicin, inulin, dulcitol, glycerol, mannitol, and sorbitol.

In addition to the bacteriologic examination just outlined, the following observations were made to determine evidence of mastitis: Appearance of sample, direct leukocyte count, sediment content by centrifugation, and reaction to the bromthymol blue test. Plastringe *et al.* (1934) divided the udder streptococci into Groups A and B as follows:

### Litmus Milk (37°C)

*Acid, acid and coagulation with partial reduction*  
*Sodium hippurate hydrolysed*



Although the nomenclature was not that of the present day, Group A (*Streptococcus mastitidis*) was the organism now designated as *Streptococcus agalactiae*. *Streptococcus dysgalactiae* was not identified in this scheme. Group Ba was readily recognized as the organism now known as *Streptococcus uberis*. However, modifications of the above procedures were constantly instituted so that by 1938 the methods used were described by Plastringe *et al.* (1938) as follows: Samples were drawn aseptically and incubated for 24 hours before examination. Slide films were then made for leukocyte count and presence of organisms. Four mm loopfuls of the incubated samples which contained chains of cocci were streaked on plates of Edwards' medium (Edwards 1933) and incubated at 37° C for 48 hours. Transfers of the streptococcic colonies were made into blood broth and replated on blood agar. Identity of the organisms obtained from the Edwards' plates was based on: Reaction in litmus milk, ability to reduce methylene blue milk (1:5000), and ability to produce an acid reaction in serum broths containing Andrade's indicator and lactose, mannitol, inulin, raffinose or salicin.

At that time Plastringe *et al.* (1938) were identifying *Streptococcus agalactiae*, *Streptococcus uberis*, and *Streptococcus pseudoagalactiae*. In addition, these organisms were classified within the Lancefield groupings as Group B for the first species, no group for the second, and Group C for the last. At the time the films were examined a partial decision was made as to whether or not streptococci were present; if no streptococci were seen and the leukocyte count was under 500,000 per ml, the sample was considered negative; otherwise the sample was streaked on Edwards' medium and the resulting streptococcic colonies, if any, were identified. However, if organisms other than streptococci were associated with 500,000 or more leukocytes per ml, the incubated sample was also streaked on blood agar and identification of the resulting colonies was carried on from there. By 1940 the milk samples were being drawn into tubes containing sodium azide to yield a final concentration of 1:20,000, and bromocresol purple to yield a final concentration of 1:5,000.

Edwards' medium was modified in 1943 because of the shortage of aesculin as reported by Plastringe and Bryan (1946). Another improvement was to employ arginine broth as described by Nivin, Smiley and Sherman (1942), methylene blue milk (1:5000), and litmus milk as a biochemical means of differentiating the streptococci. For this latter method, the colonies were picked and inoculated into chicken or beef infusion broth, incubated for 18 hours, and then inoculated into the differential mediums in 0.1 ml amounts.

As previously stated, samples containing bacteria other than streptococci were streaked on blood agar and identified by routine bacteriologic methods. Coliforms were differentiated by the IMVIC reactions of Parr (1939).

Sections for histologic examination of the udder were usually taken within two hours after death. Just prior to slaughter or at the time of pathologic examination, milk was withdrawn for final bacteriologic test. Since all of the udders were not dissected by the same person the technique varied somewhat. During the early part of this study only tissue blocks from affected areas were saved for subsequent histologic examination.

In later years each quarter was divided into three horizontal levels and each level into 6 to 10 vertical blocks much the same as Morrill (1938) suggested. The lowest or most ventral area was designated as level I, the middle as level II, and the dorsal or uppermost as level III. The areas within the respective levels were numbered 1 to 10. Number 1 was the area in the forward or anterior or lateral part of the level, whereas number 2 was in the medial or inside portion of the level. Number 3 was the lateral area, but posterior to number 1. Thus by commencing at the antero-lateral portion of the quarter the operation was carried out to secure 6 to 10 sections on all respective levels. The odd numbers were always in a lateral position in the level and the even numbers in a medial one.

Sections were fixed in Zenker's fixative or 10 percent formalin, blocked in paraffin, and stained by various methods, the routine method being hematoxylin-eosin (H & E) or Harris' hematoxylin-triosin (HHT). However, at times other stains were employed such as Glynn's Gram stain, S Gram pyronine, eosin methylene blue, Mallory's collagen, Masson's trichrome, Van Gieson's and Boehmer-Schmorl hematoxylin-eosin Y (BHEY). Fat stains such as Scharlach Rot were infrequently used. Some sections were left unstained for phase microscopy. Fifteen of the udders



were not dissected at once but were milded out and then injected under pressure with 10 percent formalin via the teat canal similar to the procedure of Spencer (1949). This method was adopted as a means of preventing "atelectasis" of the parenchyma. Richardson (1949-50) has shown atelectasis to be a complicating factor in the interpretation of histologic sections. After 48 hours the injected udders were dissected and sections for histologic study were removed.

Of the total of 138 udders available, 505 quarters were subjected to histologic examination. The number of quarters and udders were as follows:

*Organisms Associated with Mastitis (Plastring's and Hale's  
(1948) Classification or Grouping) and the Number of  
Udders and Quarters Involved.*

<i>Group</i>	<i>Quarters</i>	<i>Udder</i>
I (Normal)	158	57
II (Staphylococcus)	160	59
IIa (Physiological)	4	1
III (Str. uberis) (and dysgalactiae)	43	16
IIIc (Coliform)	39	17
IIIcp (Corynebacterium)	5	2
IV & V (Str. agalactiae)	54	18
Novoxil Mastitis	41	13
Malignant Head Catarrh	1	1
	505	184

It will be noted that the total number of udders is 184 as compared to the figure of 138 as previously given. This is accounted for by the fact that in 46 udders, different quarters were infected by different organisms.

Brucellosis mastitis was not studied as brucellosis did not exist in the herd and experimental facilities to reproduce the disease were lacking.

## RESULTS

### Histologic Observations

The histology of the normal bovine udder has been studied many times as indicated in the review of the literature. Certain histologic features deserved further consideration.

*Sebaceous Glands.* Fürstenberg (1868) described glands within the epithelium of the teat canal which he termed "Talgfollikeln," translated by De Vries (1946) as sebaceous follicles. It is rather surprising that these follicles have received so little attention, save for Mankowski's (1903) questioning their existence. The glands could be seen within the stratum granulosum and stratum spinosum at fairly low magnification (Fig. 1). Closer examination revealed them to consist of enlarged cells with a dark nucleus and

scanty or no cytoplasm in sections subjected to common fat solvents (Fig. 2). While no function has been ascribed to these cells, it is the authors' belief that they are sebaceous in character and secrete a sebum-like product which acts as a sealing agent of the teat canal between milkings. Since the whole cytoplasmic area usually was found to be clear, the cell probably functions in a holocrine manner.

*Basket Cells.* As pointed out, the basket cells have been the subject of considerable debate. When stained by Van Giesons' technique they have the appearance of muscle cells on account of their long, narrow processes and their yellowish hue (Figs. 11 and 12). Muscle in the interalveolar space can only suggest that its function is to force milk from the alveoli in accordance with Zwart's (1911) and Richardson's (1949-50) views.

The exact location of the basket cells has been the most contentious point. Phase microscopy was resorted to in an effort to clarify their position. By this method, the alveolar epithelium was seen to rest on a distinct membrana propria or basement membrane (Fig. 3). In stained sections of the same tissue, the basket cells appeared to be located outside of the membrana propria. Difficulty was experienced here inasmuch as sections stained by the H and E method failed to reveal the basement membrane (Fig. 13); consequently one had to rely on estimation and landmarks such as nuclei and conformation. The elongated cytoplasmic configuration of the basket cells could have been confused with the basement membrane, but phase microscopy revealed the existence of the controversial membrane beyond doubt.

In addition, some sections which were stained by Masson's trichrome method showed a faint line of connective tissue which could have been the basement membrane. This line was in intimate association with the alveolar epithelium and in such a position as to rule out other cell types. So it is believed that the basket cell is located outside of the basement membrane.

*Alveolar Epithelium.* Some alveoli exhibited multi-layered epithelium in a small portion of the perimeter, a fact previously reported. This finding was rather common. Although the process was essentially a hyperplasia no pathologic significance could be attached to it (Figs. 9 and 11).

*Leukocytes.* In cases of definite mastitis, leukocytes were a prominent feature of the histopathologic picture. As already stated the lymphocyte was considered to be a normal accompaniment of involution (Maximow and Bloom 1938). Yet the general tenor of most papers was that lymphocytes were present in chronic and interstitial forms of mastitis. At the inception of involution, even though the changes observed were slight, lymphocytes began to appear in the interalveolar tissue (Fig. 11). In the normal involuting udder, the lymphocytes were not particularly numerous and were evenly distributed throughout the involuting tissue. In cases of definite mastitis, the lymphocytes tended to infiltrate in much the same manner (Fig. 21), making distinction between normal and pathologic lymphocytic aggregates quite difficult.

Chu (1949) contended that a leukocyte count of 500,000 per ml. was far too high and considered that 20,000 per ml. was a better figure.

A total of 17 udders have been investigated which could be broken down into a group of udders never infected, and another group which had only one quarter infected. The latter group was clinically negative,

evidence of mastitis being found only by bacteriologic tests. The average leukocyte count for the last lactation was 56,000 per ml. for the negative group, and 81,000 per ml. for the bacteriologically-positive group. The negative quarters from infected udders average 40,000 leukocytes per ml. It must be pointed out that a certain udder had a rather high leukocyte count although the udder was negative bacteriologically and histologically (Fig. 7). Without including this udder the figures for the negative quarters would have been lowered considerably. This udder was obtained from a heifer which died suddenly from undetermined causes.

MacLeod and Anderson (1952) studied the cell counts from 10 Group I or healthy cows for the first 41 weeks of lactation. They found the leukocyte count to average 70,000 per ml. for the entire group.

In a third group of udders, seven infected quarters had a leukocyte count of 1,220,000 per ml. yet their neighboring quarters had a low count. Apparently infection of a mild nature in one quarter had no influence on its neighbors in relation to leukocyte counts.

The secretion from 17 negative quarters from a fourth group of udders in which two or more quarters were infected had an overall average of 380,000 per ml. In contrast, the secretion from the 27 infected quarters had an overall average leukocyte count of 2,210,000 per ml. Under these conditions the milk from the negative quarters showed a marked rise in leukocyte count, which still was not indicative of infection if one accepted the bacteriologic results and the absence of lesions on histologic examination.

Seven other mammary glands were classified as negative on the grounds that the leukocyte count was below 500,000 per ml., averaging 270,000, and that nonhemolytic staphylococci were the only organisms isolated. If one accepts Chu's (1949) figure of 20,000 leukocytes per ml. for milk from normal udders, the 270,000 per ml. would indicate infection, whereas with 500,000 per ml. as a base line, the 270,000 per ml. would not be significant. Yet upon histologic examination small foci of heterophils were seen in the alveolar lumina and the interalveolar tissue in one or more quarters of each udder. This finding was considered to indicate infection; and while nonhemolytic staphylococci were of low virulence they could not be considered entirely lacking in pathogenicity. Thus it appeared that a count well below 500,000 leukocytes per ml. should be considered normal, if infections with nonhemolytic staphylococci are included. An exact figure is difficult to determine.

To account for the apparent discrepancy between the relatively high leukocyte counts which were classed as negative in routine diagnostic work and the supposedly low count of normal cows, Plastring (1951) wrote: "At the present time in routine tests for mastitis control, a leukocyte count of 100,000 to 500,000 per ml. cannot be considered as positive evidence of mastitis for the following reasons: (1) These counts are usually caused by the presence for nonhemolytic staphylococci, and at times by mechanical irritation, and are seldom accompanied by clinical mastitis; (2) animals classified on the basis of counts under 500,000 leukocytes per ml. frequently shift from negative to positive; and (3) nearly 100 percent of the cows in any herd will give milk with counts of from 100,000 to 500,000 leukocytes per ml. on one or more tests if periodic tests are made during the entire lactation."

For the purposes of routine diagnostic work the above interpretation of leukocyte counts was plausible enough. However, as already shown,

histopathologic lesions did exist in udders with counts below 500,000 per ml., all of which supported the assumption that the leukocyte count of milk from strictly normal udders was lower than 500,000 per ml.

In cases where two or more quarters were infected, milk from the non-infected quarters ran high in leukocyte count. This phenomenon may have been the result of frequent contact with the etiologic agent, lymphogenous or hematogenous spread, or a sympathetic reaction.

Leukocytes frequently have been mentioned in milk smears without further differentiation. Classification of the various leukocytic types was found to be important, since the heterophil always has identified pathologic processes. In every case of mastitis, excepting some cases of coliform mastitis, the heterophil was a prominent feature. It indicated a pathologic process which should not be ignored. Sections of quarters of all animals considered to be negative bacteriologically and histologically were without heterophils. On this basis all quarters containing heterophils on histologic examination were considered as affected with mastitis.

Lymphocytes were seen in other portions of the udder, namely in the accessory glands (Fig. 14) and in perivascular cuffs on the teat wall (Fig. 4). In the latter location they appeared to be a normal cellular constituent, not concerned with leukocytes. The accessory glands of the bovine udder seemed to be analogous to the glands of Montgomery seen in the areola of man.

*Corpora Amylacea.* In the material studied, corpora amylacea occurred in two distinct forms. The common form was a darkly-staining solid concretion often smaller than the nucleus of the alveolar epithelial cells (Fig. 16). However, some of these concretions did at times form about loose epithelial cells (Fig. 15).

Occasionally corpora amylacea become imbedded in tissue, as Morrill (1938) pointed out, by having the alveolus atrophy about them. However, the case illustrated in Figure 16 demonstrated a corpus amylaceum in the cisternal membrane which was perhaps a mineralized secretion of an accessory gland.

The incidence of corpora amylacea was found to be unrelated to bacterial infection or length of lactation (Table 1).

*Colostrum Bodies.* It has been reported that colostrum bodies were leukocytes laden with colostrum. This feature together with their mononuclear structure was brought out by a case shown in Figure 18. It was interesting to note that these colostrum bodies occurred 60 days post-partum in a cow infected with *Str. dysgalactiae*. Another udder infected with *Str. agalactiae* had many colostrum bodies 12 days post-partum. A heifer which had never conceived was slaughtered at three years of age; the ducts were found to be filled with colostrum bodies. Udders from six animals which had freshened less than three days previously, failed to show a single colostrum body. From these limited observations it appeared that colostrum bodies were not nearly so common in the cow as in woman, and that they are not necessarily confined to the time of parturition. This was in accord with the findings of Frei (1925) who reported colostrum bodies in udders infected with streptococci.

Of further interest was the fact that colostrum bodies frequently had been seen by the authors in neoplasms of canine breasts. In this instance one wondered if they were purely phagocytic cells or the result of hormonal stimulation resulting from sex-linked tumors.



*Ventral Levels of the Udder.* The ventral third of the udder tended to exhibit less evidence of secretion than the dorsal portions. The region of the large ducts entering the milk cistern was surrounded by dense connective tissue. One should be cautious in the histologic interpretation of ventral levels since the supportive tissue might be easily mistaken for replacement fibrosis (Fig. 50).

### Pathologic Observations

*Classification.* As pointed out in the review of the literature, obstacles were encountered in attempting to correlate the classification of the various authors. The difficulties inherent in terminology made it impossible to be positive that such attempts at correlation were correct in each instance.

The authors agreed with Spencer (1949) who has stated that classification terminology was chiefly nomenclature. This appeared reasonable, particularly after noting Webster's (1944) definition of the word classification: "Systematic arrangement . . . in groups of categories based on definite scheme . . . usually that of a natural relationship." It was considered that Webster's idea of classification would be better met with reference to mastitis classification by employing the words acute and chronic. This was in agreement with the interpretation of Schlösser (1883), Seifried (1934) and Spencer (1949).

It appeared that the difference of classification among authors was one of description. Histologic descriptions of all authors were almost identical regardless of classification. The difference lay in the application of the words acute and chronic, relative to interpretation of the findings. Taylor (1949) defined acute as a "short and sharp course," chronic as "of long duration, a slow process and long continued."

The findings reported here indicated that bovine mastitis was almost solely an acute inflammation. Chronic mastitis, if defined on the basis of histopathology, was relatively uncommon and existed chiefly as a clinical entity. The histologic aspect dealt by and large with a process varying in intensity which attacked an area causing an acute inflammation and subsequent involution. This condition varied from no loss of tissue to extensive tissue destruction. Involution commonly was the end of the process. Following involution of an area the etiologic agent moved on to attack successive new areas, thereby giving the clinical picture of chronic mastitis.

The concept that bovine mastitis was more acute than chronic was originally proposed by Ibel (1904), who studied "gelber Galt" or streptococcic mastitis. Since this type of mastitis universally had been acclaimed to be chronic, Ibel's concept could be interpreted to visualize it as a series of acute inflammatory processes. Foci of variable intensity which proceeded to a terminal phase were designated as fibrosis. The concept proposed by the present authors differs only in that the terminal phase was a condition resembling involution, and that the tissue had some of the potentialities of corresponding normal tissue.

Although Ibel's (1904) interpretation of streptococcic mastitis was never directly supported by later workers, it strangely was never opposed. It simply was neglected. Indirect support to Ibel's concept was given by Stark (1903), Hemmert-Halswick (1933) and Chu (1949), who noted

an acute phase of streptococcic mastitis. These authors were among those who employed the terms interstitial mastitis and fibrosis to indicate Ibel's terminal phase, which he insisted brought the pathologic process to a halt rather than into a progressive form.

### General Histologic Features

*Acute Mastitis.* This was a rather versatile process. It varied from a microscopic focus involving an entire lobulus or fraction thereof (Fig. 20), to macroscopic-sized foci involving a large portion of a quarter (Fig. 30). The process may continue to repeat itself on a microscopic scale; striking a few lobuli and then forsaking them for others, it may suddenly cease altogether; or there may be a major catastrophe resulting in great tissue destruction. At times the process displayed a startling selection of sites for its destructive action. A lobulus may be entirely free and yet adjacent lobuli may be deeply involved in an inflammatory reaction.

In order to simplify reference to acute mastitis three different degrees of grades were recognized. This was in no way a proposed system of nomenclature, or classification, but merely a convenience in indicating, for the purposes of this bulletin, the intensities of mastitis seen in the various bacteriologic types of infection.

**GRADE 1 OR SLIGHT.** The histologic changes observed were slight and consisted of involvement of the alveolar and ductal epithelium. This form rarely caused changes in the cisternal regions. The epithelial cells of the affected alveolus appeared slightly hypertrophied and perhaps unduly vacuolated, a condition considered to be fatty or hydropic degeneration by previous authors. Selected sections stained by fat stains revealed excessive intraepithelial fat in many instances while nonvacuolated cells appeared granular. This was in harmony with newer concepts of fatty metamorphosis which suggested it to be an extension of albuminous degeneration. The secretion tended to be clotted and to remain within the alveolus, often attaching itself to the walls by pseudopodia-like processes (Fig. 19). Ordinarily normal milk was washed out in processing to leave patent lumina (Fig. 17). Bacteria were not seen in this form of mastitis although their presence could not be denied.

Free epithelial cells frequently were seen within the area of the lesion, although caution was necessary in interpreting small numbers of them as pathologically significant. All normal udder sections revealed some such cells. These cells were not often seen in great numbers as they tended to wash out in the process of fixation, dehydration, and the like. It was remarkable how well preserved the free epithelial cells were, particularly in a normal udder. The normal secretion seemed to act as a favorable medium for tissue culture. Probably the older epithelial cells or those undergoing necrobiosis washed out with the secreted milk since few necrotic forms were seen. These cells exhibited no evidence of phagocytic activity nor did they form giant cells as reported for human mammary glands.

In such mildly-acute lesions, the periacinar and the pericanalicular (periductal) tissue was only slightly involved. Heterophils and a few eosinophils were present in the periductal tissue, but they appeared to be migrating to the involved locale. Bacteria were not seen within the tissue, but appeared in some instances to be within the debris in the lumen. The condition either disappeared or went on to a more intense form.

**GRADE 2 OR MODERATE.** This form was merely an extension of Grade 1. It was more intense and often covered a whole lobulus or usually more. The alveolar epithelium often resembled that in Grade 1, but also exhibited some atrophic changes in the epithelium. Areas in which alveolar epithelium was sloughed off were uncommon, yet many free epithelial cells suggested considerable loss. Heterophils were very common, less so eosinophils, plasma cells, macrophages, and lymphocytes. In some cases of coliform mastitis there was a surprising shift in the leukocyte type toward predominance of agranulocytes. However, in this grade the granulocytic elements usually were seen within the lumina as well as within the periductal tissue. Their presence may be due to chemiotactic forces. The secretion was clotted and contained leukocytes, epithelial cells, and, rarely, bacteria in its meshes.

The periductal tissue did not escape involvement. In addition to the presence of hematogenous and histogenous phagocytes often there was a slight edema and definite engorgement of the blood vessels. The periductal tissue reacted to the bacterial toxins in a proliferative manner (Fig. 21), which was not unlike involution.

The cisternal membrane showed the effect of the bacterial toxins and of the exudate which constantly bathed it. The lamina propria contained infiltrating leukocytes, more often of the round cell types, and the epithelium deviated considerably from the normal double-layered type (Fig. 10) to one either hypertrophied, hyperplastic, or both. In some instances metaplasia and desquamation were seen. The individual toads were occasionally pressed one against the other by edema of the lamina propria (Fig. 48). The condition was associated with various degrees of involution; i.e., some foci were approaching complete involution whereas others were just starting. In the latter, the periductal tissue contained diffuse lymphocytic infiltration, increased connective tissue, and atrophied alveoli (Fig. 42). The heterophils were diminished and milk secretion came to a halt. Finally, a state of complete involution was reached and there was no longer any evidence of any inflammatory process (Figs. 26 and 28). This was by far the most common form of mastitis observed.

**GRADE 3 OR MARKED.** This was the form generally designated by the clinician as acute mastitis. The lesions were massive and occupied large areas (Figs. 22, 23, and 30). Usually there was necrosis with subsequent loss of architecture (Fig. 30), at times accompanied by repair. But the whole process essentially was the same as noted in Grades 1 and 2, except that it occupied a larger area and thereby was more destructive. In the involved parenchyma the details of the architecture were lost (Figs. 22 and 30), and the area was infiltrated by heterophils and macrophages. Ducts became filled with cellular debris and exudate (Figs. 22 and 35). Often the tissue adjacent to an involved area manifested changes of cloudy swelling suggesting that the nearby lesion was influencing the area next to be attacked. Thrombi no doubt aided in forming the large destructive lesions. The case illustrated in Figure 31 showed the result of a large infract. The whole process was pathologically an abscess formation.

The end result of Grade 3 was not exactly the same as Grade 2. The large necrotic areas were replaced by granulation tissue which eventually matured to form scars (Fig. 31). The pathologic process at times became completely arrested, resulting in replacement fibrosis. If, however, the activity of the infectious agent continued but was confined to a limited area, then true chronic mastitis occurred. The differences in the final results

were quantitative rather than qualitative in character. The necrotic process wiped out the structure of the tissue so that genuine involution of the involved areas could not take place, yet involution did occur in areas less involved. The intensity of the process made it impossible for the tissue to react exactly as in Grade 2.

*Chronic Mastitis.* Grade 3 mastitis sometimes resulted in a stalemate between infecting organism and the defense mechanism of the udder tissue. The invading organism was by no means overwhelmed, but became localized or confined to one locale, and the fibrous elements of the tissue proliferated in an effort to contain the organisms. Fibroblasts grew into the bacterial masses as well as around them. Lymphocytes replaced the heterophils. This latent lesion not only was a veritable powder keg, but it impaired efforts to correct the condition as bacteria were well protected against any therapeutic agent. This lesion satisfied the criteria of chronic infection since it was long continued in one place. The adjacent tissue was not particularly affected except by pressure from this granulomatoid process (Fig. 24).

### Histopathology with Respect to Etiology

Text books on pathology describe bacterial infections and their lesions in a general way. Terms such as "localized" for staphylococcic and "diffuse" for streptococcic lesions usually are employed. However, such descriptions fail to hold for infectious organisms in the bovine udder. The nature of the mammary tissue accounts for the lack of limiting factors or barriers seen in solid tissue. Actually a section of functional gland is less than one-half solid tissue. In this respect it resembles the lung (Fig. 7). But unlike the lung, the open spaces are filled with a fluid which is an excellent medium for bacteria. Thus, when bacteria are only in the milk, any active defense on the tissues' part has to reach them there. But this is difficult as the secretion moves from the alveoli down through the ducts; more important is the possibility that chemotaxis is not possible under such conditions. The pathogen is easily carried in the milk secretion so that it can establish itself in a site far removed from its origin. Thus employment of the terms "local" and "diffuse" is irrelevant.

*Staphylococcic Mastitis (Connecticut Group II Mastitis).* Staphylococcic mastitis was one of the most versatile forms of bovine mastitis observed. It occurred in all three grades of acute mastitis as well as a chronic mastitis. When it occurred as Grade 1 and 2, it perfectly imitated streptococcic mastitis and mastitis due to certain coliform types. Distinction between these types of infections on histologic grounds was impossible. Because the majority of staphylococcic cases were of moderate intensity, one could readily understand the problems of diagnosing mastitis solely on histologic grounds. However, in marked acute cases as well as in chronic types of staphylococcic mastitis there was no difficulty because masses of cocci were easily visible even in H. and E. preparations. The case illustrated in Figure 22 showed a section of an udder infected for six days with a hemolytic staphylococcus. Masses of heterophils and bacteria were seen advancing on the yet uninvolved tissue. A large duct was engorged with heterophils and bacteria. The case in Figure 23 showed a slightly older lesion, but here bacteria still were visible. In both of these cases the process was still a fulminating one, progressive and causing



marked swelling of the udders. Thus, both cases were considered to be in the acute phase of the disease. The lesions differed from those shown in Figure 24 in which the lesion was static. The heterophils had left and had been replaced by lymphocytes. Fibroblasts were proliferating and walling off the process. The udder actually was quite soft except for palpable nodules. This was considered chronic staphylococcic mastitis.

Two cases of actinomycotic mastitis, based on histologic findings were reported by Smith (1934). These cases resembled the picture of chronic staphylococcic mastitis as seen in this work. *Actinomyces bovis* or *Actinobacillus lignieresii* could not be isolated in Smith's (1934) cases, but large numbers of staphylococci were found. This suggested to Smith (1934) the possibility of botryomycosis. Runnells (1946) described botryomycosis as a chronic granulomatous infection due to *Staphylococcus ascoformans*, an organism considered by Breed *et al.* (1948) to be identical with *Staphylococcus aureus*. Since the cases of actinomycotic mastitis appeared to be similar to those reported here as chronic staphylococcic mastitis, it was felt that the cases should be considered to be staphylococcic mastitis. There seemed to be no necessity for introducing new terms for the condition.

Differences in cultural characteristics of the staphylococci, particularly in hemolysis, are well known. One might expect mastitis to be chiefly caused by hemolytic strains. In a sense this was correct since the seven cases considered to be Grade 3 and chronic mastitis all were caused by hemolytic staphylococci. In 36 cases of Grades 1 and 2 mastitis, 24 were caused by hemolytic staphylococci and 12 by nonhemolytic strains. Thus, while hemolytic staphylococci were more commonly associated with mastitis, the nonhemolytic staphylococci also were capable of causing mastitis.

Cases which had existed three months or more when examined grossly, revealed, in 15 of 40 instances, small nodules on the cisternal membrane. These have been referred to as warts. Microscopically, nodules in staphylococcic mastitis were either areas of epithelial hyperplasia or areas of squamous metaplasia. These nodules in the cisternal membrane sometimes were accompanied by round cell infiltrates in the lamina propria, edema, hypertrophy of the epithelium and sloughed epithelium. In cases of three months or more duration, there was no relationship between length and severity of mastitis on the one hand, and the lesions of cisternal membrane on the other. Mild cases of staphylococcic mastitis (Grades 1 and 2) usually showed as much change as severe cases.

Staphylococcic mastitis was common in the herd from which most of the udders were obtained. A total of 57 staphylococcus-infected quarters were obtained as compared to 15 *Str. agalactiae* infected quarters, the majority of which were recently infected. The main emphasis in the management of this herd was directed toward eliminating *Str. agalactiae* and little attention was given to staphylococcic infection. However, once the latter was well established in the udder, the disease often was as insidious and relentless as agalactiosis. The histologic changes in either condition were identical and considered to be of the same intensity. Thus, the opinion that staphylococcic mastitis was a neglected type was not an exaggeration. This latter conclusion did not consider the relative importance of one organism over the other in the bacteriologic sense. The fact that *Str. agalactiae* dominated the staphylococci when both existed in a herd, in no way minimized the importance of the latter. Furthermore,

it should be pointed out that use of the effective control measure for *Str. agalactiae* created a condition wherein staphylococci formed a favorable environment in susceptible quarters which would otherwise be infected with *Str. agalactiae*.

*Coliform Mastitis (Connecticut Group IIIc Mastitis)*. The organism involved was designated as "coliform" prior to the use of the I.M.V.I.C. system (Parr 1939), after which time it was identified as either *Aerobacter aerogenes* or *Escherichia coli*. The distinction was a bacteriologic one which could not be made histologically.

Coliform mastitis existed as Grades 2 or 3. It never existed as Grade 1 although seven cases of Grade 1 mastitis were seen in which no bacteriologic agent was isolated consistently. Some of these cases could have been caused by coliform organisms. When occurring as Grade 2 mastitis, the coliform bacteria induced no tissue changes distinguishable from streptococcal or staphylococcal mastitis. The leukocytic reaction seemed to be of some slight differential value and will be referred to below.

Grade 3 coliform mastitis was different from other types discussed. Lesions usually showed widespread necrosis, or edema and leukocytic infiltration.

If the process had existed for several days there was replacement of the necrotic tissue by granulation tissue.

When staphylococcal mastitis existed as Grade 3 the organisms were visible. This was not so in coliform Grade 3 mastitis. No organisms were seen, since they were Gram negative and intermingled with necrotic tissue.

There was another notable feature of coliform mastitis which was useful in differential diagnosis. In Grade 2 coliform mastitis, lymphocytic-type cells often were predominant (Fig. 27). This observation also held true for Grade 3 coliform mastitis with the addition of mononuclear elements (Figs. 32 and 33). Heterophils were completely absent in some cases (Table 3). The rather low number of heterophils was puzzling; one can speculate that the severe type of coliform mastitis caused considerable breakdown of lactose to lactic acid which in turn exerted a negative chemiotactic effect upon the heterophils. The massive heterophilic reaction which occurred in some cases of coliform mastitis could have resulted from the utilization of milk proteins by *Aerobacter aerogenes* to produce an alkaline environment which would have allowed the heterophils to reenter the picture. It is believed that the suppressed flow resulted in a limited lactose supply, thereby necessitating the use of proteins for survival of the organisms. This reaction of *Aerobacter aerogenes* has been known for some time (Salle 1948).

*Corynebacterial Mastitis (Connecticut Group IIIcp Mastitis)*. This type of mastitis is caused by *Corynebacterium pyogenes*, although Jorgensen (1937) declared that *Micrococcus indolicus* always was present in such cases and that this latter organism made it possible for *C. pyogenes* organisms to establish themselves.

Only two cases were available for study and both animals succumbed to the disease. Both cases belonged to category Grade 3. Large necrotic areas, masses of heterophils, and large colonies of bacteria (Figs. 34 and 35) were easily identified. If anything, this condition was more destructive than the severe cases of coliform or staphylococcal mastitis. The presence of *C. pyogenes* organisms made differentiation from coliform or staphylococcal mastitis possible and relatively easy.

In both of the udders there was a pronounced squamous metaplasia of the cisternal membrane (Fig. 36). In contrast to the distribution of metaplasia as seen in staphylococcic cases, the process tended to be continuous and imitated the stratified squamous epithelium of the oral cavity.

*Streptococcic Mastitis (Connecticut Groups III, IV, and V Mastitides).* Group III mastitis is caused by *Str. dysgalactiae* and *Str. uberis*. Cows placed in Groups IV and V yield milk containing *Str. agalactiae*. The difference between the two groups is dependent upon the leukocyte count; in Group IV cows the leukocyte count per ml. of milk is less than 500,000, whereas in Group V cows the milk contains 500,000 or more leukocytes per ml. (Plastridge and Hale 1948).

All streptococcic mastitides were considered under one heading as the histologic features were similar, with one possible exception. All three organisms produced Grade 1, and more often Grade 2 mastitis; only 2 of the total of 34 udders were not in these grades. One such case was Grade 3, whereas the other was a rather unusual condition, both of which will be described later.

The fact that streptococcic mastitis was usually Grade 1 or 2 created a diagnostic problem to the histologist since the same pathologic forms were found in coliform and staphylococcic mastitides. This problem was concerned with the parenchyma, but not the cisternal membrane. In cases of staphylococcic mastitis other authors have reported that there were more heterophil than mononuclear elements, with the opposite situation prevailing in streptococcic mastitis; their conclusions were based on examination of milk films. The present study of histologic sections did not bear out these findings. In both staphylococcic and streptococcic mastitides of the lower grades the heterophil was the chief and practically the only leukocyte. Lymphocytes were seen in both of these types of mastitis in the interstitial tissue when a lobulus was involuting, but the leukocytes in the alveolar and ductal lumina were almost altogether heterophils. Grade 2 coliform mastitis showed a predominance of lymphocytes and mononuclear cells usually in higher proportion than the heterophils. Although this feature was helpful, it was by no means a definite diagnostic criterion. Thus, no definite histologic differentiation was possible among the less intense forms (Grades 1 and 2) of staphylococcic, streptococcic, and coliform mastitides.

The subject of histologic differentiation cannot be dismissed without consideration of the cisternal membrane and its change. *Str. uberis* caused rather striking changes at times: In two of the nine cases there was a rather severe reaction. The case illustrated, Figure 45, presented a complete loss of the normal two-layered lining and replacement by stratified squamous epithelium. The lamina propria was a mass of granulation tissue. Another case of *Str. uberis* (Figs. 46 and 47) was believed to be in an earlier phase of the process. The epithelium was actually lost in some areas, and where present it was hyperplastic. In a still earlier phase infiltration of the lamina propria and slight edema was present (Fig. 44). In this stage the rather smooth outline of the multilocular membrane (Fig. 10) was disturbed and the indentations were sharp and abrupt.

According to the cases studied the situation seemed to be as follows: *Str. dysgalactiae* produced only mild changes (Fig. 44) which also occurred in *Str. uberis* and *Str. agalactiae* infections. However, the latter two were capable of more severe changes (Figs. 45, 46, and 47).



Outstanding changes in the cisternal membrane in 2 of 18 cases were caused by *Str. agalactiae*. The alterations resembled those of *Str. uberis* with the exception that hyperplasia of the epithelium was prominent. The hyperplastic process reduced the normal indentations of the cisternal membrane to mere slits. In 11 of the remaining 16 cases only mild epithelial hyperplasia existed, a condition indistinguishable from the cisternal changes produced by other streptococci. The cisternal membranes of the five remaining cases were considered normal. The changes in the two cases referred to, could create a therapeutic problem since milk and bacteria may be entrapped and thus actually be protected from the therapeutic agent (Figs. 48 and 49). This marked epithelial hyperplasia and accompanying edema was considered to be of pathognomonic importance, although its relatively uncommon occurrence limited its diagnostic value.

Pattison (1951, 1952) in a detailed study of experimentally-induced *Str. agalactiae* in the goat reported that cisternal membrane changes occurred in a matter of hours after infection. A papilliform growth appeared in the cisternal wall and stratified pavement epithelium covered the mass, which began to regress after the first few days. Within two weeks the cisternal membrane was virtually normal. When Pattison (1953) reviewed our sections, including those of the previously mentioned corynebacterial cases, he stated that the changes were essentially the same as in the goat. He further stated that the proliferations could form large branching solid bodies which could fill an entire duct or more. The inability to see this process as Pattison did was attributed to the facts: (1) that none of the cows were killed within hours after infection, (2) that infection was established for a long period with the result that the cisternal membrane was in almost constant contact with the toxic products of the offending bacteria.

Streptococcus being Gram positive, it stained darkish blue with H. and E. and special Gram pyronine stains. However, actual finding of the bacteria was difficult. Judging from the masses seen in milk smears one would expect to find organisms with great ease. This was not supported by the present observations.

As previously stated, sections were treated with Glynn's Gram stain or special Gram pyronine stains for bacteria. The sections never exhibited streptococci in the tissue, but in a few instances streptococci were seen in the lumina. Although large masses of heterophils, cellular debris, and clotted milk were present, the organisms were very scarce. When present they stained well with the techniques employed and were unquestionably recognized as streptococci. The organisms always appeared among the heterophils and the debris. Since cellular exudate and debris might be expected to be present at the site of the infected focus, bacterial organisms should be demonstrable in the same locality. Furthermore, heterophils and debris did not wash out easily.

The presence of few, if any, streptococci in such material suggested that in the presence of large numbers of leukocytes most of the organisms had been destroyed. However, Pattison and Holman (1951) saw organisms in their goat cases in the early stages or within a few hours after experimental introduction of *Str. agalactiae* into the mammary gland. Pattison (1953) saw the organisms in macrophages, lymphatic ducts, and in the supramammary lymph nodes, showing that (1) phagocytosis took place almost at the inception of the infection, and that (2) organisms were removed quickly from the scene. Bacteria were seen in 14 of 34



cases of all types of streptococcic mastitides, but often in only one section from each udder. When one considered that sometimes 30 sections per quarter were taken, the rate of occurrence was so small as to be of no diagnostic consequence. The ventral portions of the udder have been reported to be more involved than the dorsal ones, a feature reflected by the present material. In large ducts and in the cistern, the lumina were so distended that ordinarily the contents washed out in fixation. Apparently the majority of the bacteria existed in the large ducts where the changes were most common. Large numbers of bacteria in the milk suggested that this might be the case.

The organisms did not appear to live within the tissue, but within the lumina where the milk acted as a good culture medium. This fact suggested that the organism had saprophytic tendencies. However, it must have exerted some influence on the tissue or no changes would have occurred. It was believed that the changes were the result of a toxin elaborated by the organism. The thought that lactic acid might be the cause of tissue changes (Spencer 1949) did not seem plausible. Such a concept would raise the question as to whether or not an organism causing tissue changes by virtue of its lactic acid production, should be considered a pathogen. By the same token, any lactose fermenter capable of living in milk, such as *Str. lactis*, should cause mastitis, a fact not borne out by experience. Moreover, the hydrogen-ion concentration of milk from *Str. agalactiae*-infected udders often was less than that of normal milk. Even graded cases of agalactiosis with milk normal in all respects save the presence of bacteria, presented definite histologic alterations. It was believed that lactic acid played no part in the formation of pathologic changes of the udder, as only the adaptability of an organism to life within or on tissue made pathologic differentiation possible.

Two cases of streptococcic mastitis reached the intensity of Grade 3. One was identified only as a beta-hemolytic streptococcus, while the other was definitely *Str. agalactiae*. In the case of the beta-hemolytic streptococcus infection there was a violent reaction in the affected quarter which culminated in a long, branching, fibrous mass. Upon histologic examination (Fig. 51) it was found that the mass was a large cast which was filled with granulation tissue surrounded by stratified squamous epithelium. Small periductal foci of heterophils and exudate often occurred adjacent to the involved ducts and at times tended to be confluent, giving the impression that the duct was surrounded by purulent material. A similar structure has been reported in an udder infected with *Aerobacter aerogenes* (Jasper *et al.* 1946). Apparently the streptococcus established itself in the lower aspect of the teat cistern and progressed dorsally; the nearby lobuli became involved as the infectious process widened in extent, resulting in periductal foci.

The other case of Grade 3 mastitis occurred in a markedly distended quarter from a cow that visibly was ill. *Str. agalactiae* was isolated in pure culture and the leukocyte count of the secretion was over 40 million per ml. The severity of the inflammatory process was unlike any of the other cases of agalactiosis studied. Examination of sections showed extensive heterophilia, necrosis, and edema, but no organisms. The cistern and large ducts presented unmistakable squamous metaplasia. Heretofore, only relatively severe cases by *C. pyogenes* and highly toxigenic staphylococci produced any appreciable squamous metaplasia of the cisternal membrane.

The cases studied did not permit any extensive differentiation of the grades of mastitis caused by the streptococci. All streptococci produced mastitides that were largely identical with one another. There appeared to be very severe mastitides in the cases caused by *Str. uberis* and *Str. agalactiae*, but differentiation between these with respect to degree was impossible.

The streptococcic mastitides were acute inflammatory processes rather than chronic ones. To illustrate the acute character of streptococcic mastitis, or for that matter any of the milder forms of coliform and staphylococcic mastitides, three cases of agalactiosis will be reviewed.

CASE 1. Six-year-old cow, four calves, 120 days lactation, agalactiosis 60 days, four million leukocytes per ml. of milk. In the lower third of the infected quarter approximately two-thirds of the lobuli were involuted, the periductal tissue was only slightly infiltrated by lymphocytes, and sometimes not at all (Figs. 25, 26, and 28). Masson's trichrome and Van Gieson's stains revealed the periductal elements to be connective tissue of relatively cellular character. The remaining one-third of the lobuli were either normal-functioning lobuli, or were involved to the extent of Grades 1 and 2 mastitis. In the lobuli only partially involved, one could follow the process from its inception to the terminal phase of involution.

The process began as an acute inflammation represented by heterophils in the lumina, and slightly vacuolated alveolar epithelial cells which were hypertrophied in places, with some cells free in the lumina (Fig. 38). Slightly more advanced areas (Fig. 39) contained heterophils in thickened periductal tissue. Other lobuli imitated exactly those from cows of a longer duration of infection (Figs. 40, 41, and 42) and showed ever increasing periductal tissue with heterophils decreasing in number, but with increasing numbers of lymphocytes. Near the end of the process a state was reached (Fig. 43) wherein the lymphocytes had begun to leave and involution was almost complete. In sections of the dorsal levels of the quarter the proportion of the involuted lobuli to functional or partially functional lobuli became lower. Thus, near the dorsal portion of the udder, only a few lobuli were involuted or inflamed, whereas most were normal. Another quarter from this cow which had been infected for four months was identical in every respect, whereas a negative quarter was judged normal. The cisternal membranes in all four quarters were negative.

CASE 2. Four-year-old cow, two calves, 23 days lactation, agalactiosis one year, five million leukocytes per ml. of milk. In the affected quarter, about one-half of the lobuli were involuted in the lower two-thirds. As one approached the dorsal portions of the gland the number of functional lobuli increased while the number of inflammatory foci became less. Here again all stages were found from normal to completely involuted lobuli.

CASE 3. Eight-year-old cow, six calves, 45 days lactation, agalactiosis five years, 0.09 million leukocytes per ml. of milk at time of slaughter. The udder or affected quarters differed but slightly from that described in Case 2.

More remarkable was the fact that two other cows, one infected for 6 years and another for 10 years, contained surprisingly many presumably functional lobuli.

The above cases served to illustrate the contention that the appellations which were acute or chronic to mastitis, depended largely upon the interpretation of the terminal phase as fibrosis or involution, respectively. Chronic inflammation was visualized as demanding a long continual inflam-

matory process in one area. Although agalactiosis hitherto was generally accepted as a chronic mastitis, the progressive character of the infection was likewise accepted. (Morrill 1938, Chu 1949, Spencer 1949).

There are two factors which should determine the interpretation of the histologic finding in respect to the terminology of acute and chronic. One is the constancy of the location of the inflammatory process and the other the nature of the terminal phase ordinarily referred to as fibrosis.

If one considers mastitis as a disease of the quarter as a whole, the term chronic would be applicable to the condition. However, such a consideration may not be proper; it would be better to consider the basic unit of the mammary gland, the lobulus, and how it and its neighbors react to the infectious agent. One can speak of a whole udder as mastitic, infected, or inflamed. But in such a generalized infected quarter one can usually find some normal tissue. The histologist sees the quarter as an organ only partially involved, with small or large infected areas (Figs. 20 and 23), and areas of so-called fibrosis (Figs. 8 and 26), with transitional stages between these two phases (Fig. 42). In a case clinically designated as chronic mastitis, the histologist sees not only a mass of fibrosed tissue or areas of interstitial mastitis, but also small acute foci on the way to fibrosis. These small acute foci are the aggressive and damaging principle in the mastitis process.

Hesitancy to accept this view may be due to the microscopic size of some of the foci. Some may find it difficult to accept a mere pin point pustule as an acute infection in the same sense as a carbuncle. But this discrepancy in size is the only difference. The carbuncle may be considered as a duplication of the pustule on a grand scale.

So-called fibrosis, particularly its development, had been the main stumbling block in the histopathologic analysis of mastitis. It has been noted that involution owing to mastitis is difficult to distinguish from normal involution (Lubke 1934, Olafson 1948, Zobel 1902). It was concluded from this work that acute mastitis of slight intensity terminated in complete involution of the affected parenchyma. Yet the end results were indistinguishable from those brought about by normal functional regression. The area in Figure 26 was found amidst relatively normal lobuli and other lobuli which contained heterophils and exudate so that the question arose as to the origin of the involution. This question could not be answered on morphologic grounds. The fact remained, however, that involution caused by an infectious agent and involution of the normal type presented the same picture.

The lobulus attacked by an organism showed a defensive structure. Heterophils were the earliest to enter the scene. Cessation of the milk flow came later, in itself a very good defense mechanism because the medium for bacterial growth was partially lost. Unless the organisms had succeeded in establishing themselves in the tissue (Fig. 22) they had to move on in order to survive. Since the available material suggested this view, the authors were inclined to regard the terminal phase of mastitic foci as involution in the sense of Ibel (1904).

In the event that the above theory was true, the question arose as to the ability of the involuted lobuli of mastitis to regenerate. Study of the present sections invariably revealed a highly cellular connective tissue in the interalveolar regions in normally-involuting and also in mastitic-involuting udders. This type of connective tissue was believed to be the same in both instances and to represent the specialized type as reported



in human mammary glands in which such tissue undergoes atrophy upon regeneration of the lobuli. There appeared to be some evidence of regeneration of the mastitis-involved lobuli in the sections examined.

If fibrosis is the terminal phase, and progressive in character, glands infected for several years should be completely fibrosed and nonfunctional. If fibrosed lobuli regenerate at least in part, then the udder would continue to function although not as efficiently. In support of this argument, it may be reiterated that cases of several years duration did contain many functional lobuli, in fact about the same number as those of about one year's duration. Furthermore, the ventral portions of the quarter usually contained many partially functional lobuli (Figs. 38, 39, and 40). It was believed that Grades 1 and 2 acute mastitis resulted in an involution which was partially capable of regeneration, and that these partially-regenerated lobuli again became infected. Whether or not the involuted lobuli following infection maintained the same potentialities for functional recovery as those following the normal physiologic process was not determined.

### PATHOGENESIS

Pathologic forms and etiologic types already have been discussed. It remains to consider here the modes by which the organisms move from one site to another. Investigation of this phase of pathogenesis had to rely on circumstantial evidence as did much of the histopathologic study of mastitis. Observation of large heterophil aggregates and cellular debris in ductal lumina and corresponding observations of similar foci in communicating ducts were indicative of ductal spread. Lesions far removed from a generally involved area were presumably ascribed to hematogenous and lymphogenous spread. However, one could never be certain that such a spread actually had taken place. Consideration of the complex branching of the ductal system always opened up the possibility of far removed lesions resulting from infection carried via the ductal route even to remote areas.

Clotted milk has been stated to be the cause of milk pools in the ductal system, according to Spencer (1949). Movement of the udder could result in much liquid accumulation being carried up the ductal system, and if infected, contribute to an extension of the mastitis process. The present histologic material exhibited many pictures that were suggestive of this phenomenon. Thus, the writers believed that transportation of infectious agents via the ductal system was aided by dammed-up milk secretion.

In direct support, a case is illustrated in Figure 38 where the spread from one alveolus to another is evident. That local disturbance in pressure relationship exists is suggested by a lobulus with some dilated alveoli in Figure 37. The alveolar epithelium is flattened and the alveoli is dilated to a point of cystic formation indicating a lack of secretory activity. The pressure in an obstructed duct is the likely explanation, the duct being probably an intralobular one as only a portion is distended. Furthermore, the dilation is the only abnormal feature of these particular alveoli. They present no evidence of infection, yet dammed-up secretion could easily carry organisms to them. This, to be sure, is a small scale instance of spread. However, the fact that interlobar and intralobular ducts often were engorged with leukocytes and debris shows the potentialities of this mode of spread on a large scale.



Successful hematogenous and lymphogenous spread (Kitt 1886, Stark 1903) presupposed the occurrence of emboli. However, the available material failed to produce evidence of emboli in Grades 1 and 2. In Grade 2, mastitides-obstructed blood vessels were seen which may have developed embolically, but also could have been the result of extravascular pressure from existing edema. In Figure 31 a large necrotic area is shown which appears to issue from an infarct. The cause of the thrombus may have been an embolus, but it also could have been the result of direct vascular injury. The possibility of hematogenous and/or lymphogenous spread by septic or bacterial emboli cannot be denied as it has been reported by clinicians that pneumonia—which has been said to resemble mastitis—may be embolic in origin. Furthermore, Pattison and Holman (1951) actually saw *Str. agalactiae* in macrophages and in the lymphatic ducts. The organisms eventually found their way to the supramammary lymph nodes where they were presumably destroyed. However, the experience gained from this study points to ductal transmission as the cause of spread in the great majority of cases.

The cases of so-called silver oxide mastitis indicated that lymphogenous spread was real enough. In 4 of 13 cases studied, one could see particles of silver in the lymph nodes (Table 4). The silver oxide was found in the udder embedded in the epithelium of the alveoli and ducts as well as in the interalveolar tissue. Apparently the silver oxide first spread in the udder by means of the ductal system and then was absorbed into the tissue. The shortest interval between a single injection and slaughter was one week; in this case silver particles were seen in the lymph nodes.

Failure to find uncontestable evidence of a hematogenous and lymphogenous spread of bacteria, plus the efforts of others to infect the udder consistently by injection of pathogens into the blood stream supplying the udder, led the authors to believe that these routes were of minor importance in the spread of infection from one portion of the gland to another. Furthermore, the occurrence of periarteritis, endarteritis or phlebitis was not observed. As a matter of fact, arteries and veins were regularly seen amidst infected areas and appeared unscathed. This fact suggested that the opportunity for thrombus and embolus formation was not great.

What happens after bacteria have established themselves in an area has been described previously. Essentially the story is shown in Figures 19, 20, 21, 38, 39, 40, 41, 42, and 43. First there is migration of granulocytes to the area in all forms of mastitis except the coliform one, which often is combated by mononuclear elements. The infiltrating cells travel by way of the interalveolar tissue after leaving the nearest blood vessels. The epithelium becomes unduly vacuolated and begins to slough off. The interalveolar or periductal connective tissue increases in thickness owing to the multiplication of fibroblastic elements; at this time the connective tissue is highly cellular. Other phagocytic cells such as lymphocytes, histiocytes, and plasma cells begin to appear on the scene, particularly as the affected lobuli approach involution (Figs. 42 and 43). The end phase can be seen in Figures 26 and 28 where the periductal connective tissue had multiplied at the expense of the alveoli. The latter are atrophied to a great extent so that only a few alveoli and interlobular ducts remain. Lymphocytes clean up the resulting debris and then tend to disappear. This is the pathogenesis of Grades 1 and 2 mastitis.

Grade 3 mastitis behaves much the same only on a larger and more intense scale. Clinically, Grade 3 mastitis may subside in a matter of a

few days. In severe cases as shown in Figures 29, 30, and 35, there is evidence of repair although the condition has existed for only a few days.

Unfortunately no cases of agalactiosis were available which were of less than two months duration. In two quarters of two months duration there was so much involution as to lead one to believe that the involutionary process had started in a week or two after onset. In Ohlen's (1934) case of a quarter infected artificially with a streptococcus and slaughtered a week later, there was an increase of interalveolar tissue. Another quarter infected two weeks prior to the one mentioned was almost completely involuted. Furthermore, the ravages of the disease were involving the dorsal portions whereas the lower parts of the quarter were relatively quiescent.

Four cases of staphylococcic mastitis were studied by the author in which two quarters of each mammae had been infected for less than 30 days; the exact time of onset was not determined. In one case no apparent changes could be detected; in the remaining three cases there was a definite involution of the lobuli, particularly as compared to the noninfected quarters.

If one considered how rapidly clinically-acute mastitis reacted in Ohlen's (1934) cases, the writers' observations in agalactiosis of two-months duration, and the findings in Grades 1 and 2 staphylococcic mastitis of less than 30-days duration, it appeared that the mild forms of mastitis actually may cause involution to start about two weeks following infection.

## VIRAL MASTITIS

While no actual work was done with milk or udder tissues in relation to possible viral mastitis, some comment should be made about the condition inasmuch as seven cases were consistently bacteriologically negative, yet did have histologic lesions (Table 2). These cases were not considered as viral mastitis. In each instance heterophils were a prominent feature, which at least suggested that the infection was of bacterial origin. Viral infections have been said to be generally characterized by the presence of mononuclears. The seven cases in this study in no way differed histologically from known cases of Grade 1 staphylococcic or streptococcic mastitis and there was no reason for designating them as anything but bacterial mastitis.

Peterson *et al.* (1938) gave a histologic description of an udder which they thought was infected by a virus. They attempted transmission to two other cows by using ground udder material, but failed to secure conclusive results. Photomicrographs of the affected udder proved to be of no help since they showed either normal or involuted udder tissue. Peterson's *et al.* (1938) histologic descriptions mentioned very few heterophils and usually lymphocytes, plasma cells, and macrophages. This description did not fit any of the present cases, although it resembled mild coliform cases more closely than those of staphylococcic or streptococcic mastitides. However, they mentioned wide-spaced interlobular tissue, which condition the writers saw only in Grade 3 mastitis and then usually as edema.

## INCIDENTAL MASTITIS

The udder was examined from an 18-months-old heifer which died of a disease clinically resembling malignant head catarrh. Histologic examination of the brain revealed a nonpurulent encephalitis, which has been

mentioned as a feature of the disease (Hutyra *et al.* 1946). Comparison of udder sections (Fig. 60) with normal sections (Figs. 5 and 6) revealed a marked interstitial infiltration of lymphocytes. This has not been previously reported to the writers' knowledge, but the lesions should not be considered startling. The virus, according to Hutyra *et al.* (1946), is known to cause changes in the ectodermal portions to which the udder tissue belongs.

*Silver Oxide Mastitis.* Therapeutic doses of silver oxide have been reported to produce acute mastitis followed by fibroblastic activity, according to Andberg and Weirether (1943). Their photomicrographs, accompanying this report, appeared to resemble Grade 2 mastitis. In the present investigation, udders which had been treated with silver oxide were available, but they were infected prior to treatment so that they were considered of doubtful value in determining the effect of silver oxide on the tissue.

A feature seen in these cases, however, was the presence of silver oxide in the udder and lymph nodes. The silver particles were represented by small brownish black pigment granules, about 8 to 20 microns in diameter. These particles were seen in the alveolar epithelium and interalveolar tissue, as well as in the sinuses of the lymph nodes in four of six cases which had been treated at least six months previously. This observation indicated a slow absorption of the silver (Table 4).

The fact that the silver particles were absorbed into the lymphatic system was the chief reason for mentioning the findings on silver-oxide-treated udders. The findings signified that material injected into the udder may reach the blood stream via the lymph, and that the secretory surfaces of the udder were capable of absorbing therapeutic material infused into the udder, although at a slow rate.

## SUPRAMAMMARY LYMPH NODES

Textbooks of pathology generally describe three pathologic features of the lymph node: Acute lymphadenitis, chronic lymphadenitis, and neoplasia. Neoplastic changes in the bovine supramammary lymph nodes appear to be uncommon. Two cases were seen among the cases studied and both were considered to be malignant lymphoma. The nodes were grossly enlarged to about twice the normal size, and presented microscopically an almost solid mass of lymphocytes and lymphoblasts with little evidence of stroma. One had fist-sized mesenteric lymph nodes and marked infiltration of the myocardium by lymphocytic-type cells.

Acute and chronic lymphadenitis were the most frequent complications of mastitis. Acute lymphadenitis was easily determined but was seen only twice. Furthermore, it occurred in Grade 2 acute mastitis and not in fulminating forms of mastitis. The nodes appeared grossly normal, but on microscopic examination sinusoids were found to be engorged with heterophils and lesser numbers of lymphocytes and reticulo-endothelial cells (Figs. 54 and 55).

Chronic hyperplastic lymphadenitis would be a better term than chronic lymphadenitis as definite hyperplasia existed. There was expansion of the reactive centers by lymphoblasts and reticulo-endothelial cells. The reactive centers were well defined and usually did not merge (Fig. 53). The cortical hyperplasia often encroached on the medullary portion of the node.

It was in this medullary portion of the nodes where difficulty in interpreting the findings was encountered. Sclerosis has been reported by Staack (1932), in cases of fibrotic mastitis. However, some lymph nodes from normal animals appeared sclerotic, in fact large areas of connective tissue often were seen. Eleven udder halves were selected which always had been negative bacteriologically and in which the leukocyte count of the milk was below 500,000 leukocytes per ml. No lesions were seen in the udders on microscopic examination. On examination of the nodes a condition as shown in Figure 52 was common. The sinusoidal walls were quite prominent and at times were definitely thickened, as in Figure 58. In 6 of the 11 cases (Table 10) the nodes were considered to be sclerotic, yet otherwise normal. This led to the belief that the sinusoidal walls in the mature cow tended to be prominent. However, if the medullary portion of the node was both sclerotic and also exhibited endothelial proliferation (Figs. 56 and 57), or if follicular formation appeared amidst the sclerotic areas, then the medullary portion was considered pathologic. These changes accompanying chronic hyperplasia of the cortex represented the primary pathologic features of the supramammary lymph nodes in bovine mastitis.

The cortical hyperplasia in affected lymph nodes was apparently responsible for the enlargement as shown in Table 5 to 10. In Table 10 the measurements of the right and left supramammary lymph nodes were combined since it was found, by applying the analysis of variance to the right versus the left lymph nodes, that there was no significant difference. However, by applying the analysis of variance between and within the data employed to form Tables 5 to 9 it was found that a highly significant difference was one of size believed to be due to cortical hyperplasia of the infected lymph nodes. It should be admitted that statistical analysis of this problem was difficult and subject to criticism. The age of the animal, the number of quarters infected, and the duration of the disease were variables impossible to take into account. However, it was the writers' opinion that the highly significant difference was indicative of a pathologic change in the supramammary lymph nodes.

The first perceptible change was a sinus catarrh followed by cortical hyperplasia and sclerosis. In the cases studied there was no evidence of atrophy such as Staack (1933) reported in long-standing cases of mastitis. The general structure of the lymph nodes remained intact although hypertrophy occurred.

Hemorrhage was seen infrequently in the lymph nodes and if so, was confined to the medulla (Fig. 59).

Eosinophils were common in the lymph node in most mastitis cases. Generally, the granulocytic infiltrates existed as a dozen or so cells scattered throughout a sinus. There appeared to be no consistent reactions in the area in which they occurred. Organisms could not be recognized within these areas. Such cases were considered to represent chronic lymphadenitis since the granulocytic leukocytes apparently did not alter the chronic hyperplasia.

It should be pointed out that although acute mastitis was the chief picture within the udder in most mastitis, the lymph nodal changes usually were chronic in character. Apparently repeatedly developing foci of acute mastitis in the udder parenchyma called forth overlapping responses in the lymph nodes, which expressed themselves as a chronic reaction.



Changes in the lymph nodes of cows affected with mastitis appear to result from bacterial toxins produced in the udder and absorbed into the lymphatic system.

## SUMMARY AND CONCLUSIONS

One hundred and thirty eight bovine udders were studied microscopically and bacteriologically. With the exception of eight, the udders were from a large brucellosis-free herd and were collected over a span of 20 years.

### Normal Udders

1. Large sebaceous cells were present in the stratum spinosum and stratum granulosum of the epithelium of the teat canal.

2. Basket cells resembled smooth muscle cells and existed only on the interalveolar or interstitial side of the basement membrane. The latter appeared to be a definite reticular structure.

3. The alveolar epithelium was ordinarily one layer in depth, but instances were seen wherein it was several layers deep. Such phenomena were confined to isolated portions of the alveolus.

4. The leukocyte count of milk from 17 bacteriologically- and histologically-negative udders was 56,000 leukocytes per ml. The leukocyte count of milk from seven bacteriologically-negative but histologically- positive udders was 270,000 leukocytes per ml. It was concluded that a leukocyte count of 500,000 per ml. is too high for milk from strictly-normal udders.

5. Lymphocytes increased in numbers in the interalveolar tissue at time of involution in normal udders; they formed diffuse lymphocytic aggregates. Often a picture of so-called interstitial mastitis was simulated. Caution should be employed in designating a condition as pathologic solely on the basis of finding lymphocytes.

6. Heterophils were present in the alveoli and periductal tissue in those instances where a definite mastitis existed. Their presence was considered pathognomonic for mastitis.

7. Corpora amylacea were of two types: One was a small solid homogeneous concretion, whereas the other was a large nucleated body consisting of material precipitated around free alveolar epithelial cells.

8. Colostrum bodies were seen in the udders of some recently parturient cows. They were seen in the udder from one cow that was 60 days post-partum. The colostrum bodies appeared to be mononuclear cells.

9. The ventral portions of the normal udder tended to be quite fibrous. This condition was considered to be a structural means of supporting the large ducts. The term fibrosis should be cautiously employed when applied to the ventral portion of the udder.

### Mastitic Udders

1. *Acute Mastitis.* Acute mastitis varied from a microscopic focus involving an entire lobulus or less, up to a macroscopic focus. This form was divided into Grade 1 (slight), Grade 2 (moderate), and Grade 3 (marked). The grades differed chiefly in intensity.

Clinically, Grades 1 and 2 have usually been designated by other authors as chronic mastitis, whereas Grade 3 has been designated as acute mastitis.

All three forms, when examined histologically, showed acute foci constantly repeating themselves in new portions of the udder. The acute foci resulted in a terminal phase not unlike involution in Grades 1 and 2. In Grade 3 the end was necrosis and replacement fibrosis with the infectious agent frequently present in the tissue.

The terminal phase was considered to be involution, which was looked upon as a defensive reaction of the udder parenchyma. The involution resulted in cessation of milk production and caused invading organisms to migrate to productive areas unless it had succeeded in establishing itself in the tissue.

2. *Chronic Mastitis*. Chronic mastitis represented a stalemate between the invading organism and the udder tissue. The etiologic agent was localized. A granulomatous process resulted. It was not a common condition.

3. *Etiology and Histopathology*. Differentiation by histologic method of mastitides with respect to the etiologic agents was not always possible. Grades 1 and 2 mastitides tended to resemble one another closely, regardless of the causative agent.

**STAPHYLOCOCCIC MASTITIS (CONNECTICUT GROUP II Cows)**. This etiologic factor occurred in all three grades of mastitis. Grades 1 and 2 acute mastitides were indistinguishable from coliform and streptococcic mastitides of the same intensity. Grade 3 was identified by the presence of the organism, which also was seen in the chronic form. The staphylococcic type tended to form plaques of squamous metaplasia upon the cisternal membrane.

**COLIFORM MASTITIS (CONNECTICUT GROUP IIIc Cows)**. This type occurred as Grade 2 and 3 acute mastitis. Grade 3 was differentiated from most other Grade 3 forms by the apparent absence of bacteria in the sections studied, perhaps because they could not be distinguished with the stains used. A feature of some cases was a decrease or absence of granulocytic leukocytes. The cisternal membrane became hyperplastic in cases of several months duration.

**CORYNEBACTERIUM PYOGENES MASTITIS (CONNECTICUT GROUP IIIcP Cows)**. This type was always Grade 3 and particularly destructive. Masses of bacteria, heterophils, necrotic debris, and marked squamous metaplasia of the cisternal membrane served to identify it.

**STREPTOCOCCIC MASTITIS (CONNECTICUT GROUP III, IV AND V Cows)**. All of the types of streptococcic mastitides studied tended to resemble one another and occurred as Grades 1 and 2 except in two instances. In this study *Str. dysgalactiae* caused the mildest form of mastitis, whereas *Str. uberis* and *Str. agalactiae* appeared to be about equal in their capabilities to elicit pathologic changes. Long-continued cases of the latter caused marked epithelial hyperplasia and narrowing of the folds of the cisternal membrane.

Streptococci were rarely seen in the cellular exudate and never in the tissue. It was concluded that the organisms dwell solely in the milk secretion as did coliform and staphylococcic organisms in Grades 1 and 2. It was tentatively concluded that the effect of the organisms upon the tissue was caused by exotoxins elaborated by the milk-dwelling organisms.

The streptococcic organisms of Grades 1 and 2 mastitis formed small acute foci which in turn caused involution of the affected parts. The involuted lobuli appeared to have some regenerative ability because some of the protracted cases were almost as functional as cases of short duration.

Mastitis appeared to spread from one locale in the udder to others chiefly by means of the ductal system. Lymphogenous and histogenous spread apparently were of little consequence. Lymphogenous spread could have occurred since udders injected with silver oxide revealed the material in the supramammary lymph nodes.

No cases of mastitis were seen which could have been considered to be of viral etiology. Some cases were negative to bacteriologic tests (findings of nonhemolytic staphylococci and less than 500,000 leukocytes per ml. of milk were regarded as negative) but showed histopathologic lesions resembling Grade 1 acute mastitis, and were supposed to be of unrecognised origin. One case of malignant head catarrh in a virgin heifer showed marked interstitial lymphocytic infiltration of the udder.

4. *Lymph Nodes.* Normal bovine supramammary lymph nodes of mature animals showed rather fibrous sinusoidal walls, a fact leading to difficulty in the interpretation of chronic lymphadenitis. The latter was the chief change of the lymph nodes in mastitis and was characterized by cortical hyperplasia, causing a statistically significant increase in macroscopic dimensions. Acute lymphadenitis was relatively uncommon.

## BIBLIOGRAPHY

- Adler, H. E. and Migaki, H.: Cell Types Present in Milk of Cows in a Chronic Staphylococcal Mastitis. *Herd. Vet. Med.*, **46** (1951): 89-92.
- Andberg, W. G. and Karlson, A. G.: Biopsy of the Bovine Mammary Gland in Connection with Mastitis Studies. *Corn. Vet.*, **32** (1942): 237-240.
- Andberg, W. G. and Weirether, F. J.: The Effect of Chemotherapeutic Agents on the Normal Bovine Gland: I. The Effect of Novoxil. *Amer. Jour. Vet. Res.*, **4** (1943): 134-142.
- Arnold, J. P.: Anatomy and Pathology of the Bovine Teat. *Jour. Amer. Vet. Med. Assoc.*, **116** (1950): 112-116.
- Baum, H.: Das Lymphgefäßsystem des Rindes. (1912). Original not seen. Cited by Staack (1933).
- Benda, C.: Das Verhältnis der Milchdrüse zu den Hautdrüsen. *Dermat. Zeitsch.*, **1** (1894): 89-110.
- Bizzozero, G. and Vassale, G.: Ueber die Erzeugung und die physiologische Regeneration der Drüsenzellen bei den Säugethieren. *Virch. Arch. Path. Anat.*, **40** (1887): 155-214.
- Boyd, W. L.: Textbook of Pathology. 5th Ed., Lea and Febiger, Philadelphia (1947): 698-701.
- Breed, R. S., Murray, E. G. D. and Hitchens, A. P.: *Bergey's Manual of Determinative Bacteriology*. 6th Ed., Williams and Wilkins Company, Baltimore (1948): 252-253.
- Broadhurst, Jean, Cameron, Gladys, and MacLean, M. Estelle: A Filtrable Virus Isolated from Mastitis Cows. *Corn. Vet.*, **29** (1939): 261-270.
- Brouha: The Histologic Phenomena of the Secretion of Milk. (Title trans.) *Anat. Anz.*, **27** (1905): 467. Original not seen. Cited by Turner (1933).
- Bryan, C. S. and Meyer, D. B.: The Effects of *Brucella Abortus* Infection of the Udder on the Quality of Milk. *Jour. Amer. Vet. Med. Assoc.*, **89** (1936): 199-205.
- Bushnell, L. D.: An Attempt to Demonstrate a Virus as the Cause of Mastitis in Cattle. *Jour. Bact.*, **44** (1942): 393.
- Christiansen, M. and Nielsen, F.: *Proc. 12th Intern. Vet. Congr.*, **2** (1934): 548. Original not seen. Cited by Munch-Petersen (1938).
- Chu, S. J.: Bovine Mastitis: A Comparison of the Value of Diagnostic Methods. *Jour. Comp. Path. and Ther.*, **59** (1949): 81-90.
- Coolidge, L. H.: A Study of the Presence of *Bact. abortus* (Bang) in Milk. *Mich. Agric. Exp. Sta. Tech. Bul. No. 33* (1916).
- Czerny: Ueber das Kolostrum. *Prager med. Wchnsch.*, **15** (1890): 194.
- De Vries, L.: *German-English Science Dictionary*. 2nd Ed., McGraw-Hill Book Co., Inc., New York and London (1946).
- Diernhofer: Die wissenschaftlichen Grundlagen der gegen gelben Galt benutzten Heilverfahren. *Tierärztl. Rundsch.*, **35** (1929): 385.
- Duran-Jorda, F.: Cell Contents of Milk. *Nature*, **154** (1944): 704. Original not seen. Cited by Adler and Migaki (1951).
- Edwards, S. J.: A Selective Medium for the Diagnosis of *Streptococcus Mastitis*. *Jour. Comp. Path. and Ther.*, **46** (1933): 211-217.
- Ellenberger, W. and Baum, H.: *Handbuch der vergleichenden Anatomie der Haustiere*. Aufl. 16, August Hirschwald, Berlin (1915): 596.
- Emmerson, M. A.: Studies on the Macroscopic Anatomy of the Bovine Udder and Teat. M. S. Thesis, Iowa State College Library (1928).
- Emmerson, M. A.: Anatomy of the Udder. Chap. 1. From: Little, R. B. and Platridge, W. N.: *Bovine Mastitis*. McGraw-Hill Book Co., Inc., New York and London (1946): 9-62.
- Emminger, A. C. and Schalm, O. W.: The Effect of *Brucella Abortus* on the Bovine Udder and Its Secretion. *Amer. Jour. Vet. Res.*, **4** (1943): 100-109.
- Ernst, W.: Ueber Milchstreptokokken und Streptokokken-mastitis. *Monats. f. prakt. Tierheilk.*, **20** (1909): 515-518.
- Espe, D.: Secretion of Milk. Iowa State College, Ames (1946): 9.
- Faber, V. and Rottenstein, Magda: Die Riesenzellen bei chronischer Mastitis. *Frankf. Zeitsch. f. Pathologie*, **47** (1934): 173-180.
- Fitch, C. P. and Bishop, L. M.: *Br. abortus* in the Bovine Udder and Its Effect on the Chemical Composition of the Milk. *Corn. Vet.*, **24** (1934): 25-29.
- Foust, H. L.: The Surgical Anatomy of the Teat of the Cow. *Jour. Amer. Vet. Med. Assoc.*, **98** (1941): 143-149.



- Franck: Handbuch der Tierärztlichen Geburtshilfe. Berlin (1876): 548.
- Frei, W.: Milchdrüse. From Joest, E.: Spezielle pathologische Anatomie der Haustiere. Berlin, **4** (1925): 31-40.
- Friedemann, O. H.: A Study of a *Bact. abortus* Infected Udder. Thesis, Mich. Agric. College, (1922).
- Fürstenberg, N. H. F.: Die Milchdrüsen der Kuh, ihre Anatomie, Physiologie, und Pathologie. Wilhelm Englemann, Leipzig (1868): 1-216.
- Gibbons, W. J.: The Histopathology of Mastitis. Corn. Vet., **28** (1938): 240-249.
- Gill, D.: Vet. Jour., **89** (1933): 159. Original not seen. Quoted by Munch-Petersen, E. (1938).
- Gonzales Alvarez, R.: Algunas observaciones en torno a las lesiones histológicas de la mastitis estreptocócica de la vaca. An. Esc. sup. Vet. Madrid, (1935): 49-53.
- Guillebeau: Studien über Milchfehler und Euterentzündung bei Rindern und Ziegen. Landwirtschaftliches Jahrbuch, **4** (1890): 27.
- Hadwen, S.: Microscopic Detection of Mastitis. Amer. Jour. Vet. Res., **2** (1941): 11-18.
- Hadwen, S. and Gwatkin, R.: The Detection of Abnormal Cow's Milk by Microscopic Methods. Canadian Jour. Res., **17** (1939): 225-244.
- Hammond, J. A.: The Physiology of Reproduction in the Cow. University Press, Cambridge (1927): 59-76, 168-178.
- Heidenhain: Die Milchsekretion. Hermann's Handb. d. Physiol., **5** (1883): 374-380.
- Hemmert-Halswick, A.: Sitzungsbericht der Berliner Tierärztlichen Gesellschaft. Berl. tierärztl. Wehnschr., **48** (1932): 538.
- Hemmert-Halswick, A.: Zur pathologischen Anatomie der Streptokokken-mastitis des Rindes. Berl. tierärztl. Wehnschr., **49** (1933): 114-118.
- Hess, E.: Erkranken des Euters. Bayer-Fröhner, Handbuch der tierärztlichen Chirurgie und Geburtshilfe, (1911): 241-243, 250-251.
- Hess und Borgeaud: Eine kontagiöse Euterentzündung, gelber Galt genannt (mastitis catarrhalis infectiosa). Schweizer Arch. f. Tierheilk., **30** (1888): 164-165.
- Himstedt, K.: Beitrag zur Pathologie der Streptokokken-Mastitis. Inaugural Dissertation, Hannover (1927).
- Hofstad, N. S.: The Changes Produced by *Brucella abortus* in the Milk and Udder of Cows Infected with Bang's Disease. Corn. Vet., **32** (1942): 289-294.
- Holm, G. C.: A Histological Study of Bovine Udder Parenchyma. Vet. Med., **32** (1937): 163-167.
- Hopkirk, C. S.: A Method for Control of Mastitis in Dairy Cows. Aust. Vet. Jour., **9** (1933): 53. Original not seen. Cited by Adler and Magaki (1951).
- Huttyra, F., Marek, J. and Manninger, R.: Special Pathology and Therapeutics of the Diseases of Domestic Animals. 5th Ed., Alexander Eger, Inc., Chicago, **1** (1946): 485.
- Ibel, J.: Die mikroskopisch-anatomischen Veränderungen beim gelben Galt (kontagiöse Galaktophoritis) des Kuheuters. Arch. f. wissensch. u. prakt. Tierheilk., **30** (1904): 571-572.
- Ingleby, Helen: Normal and Pathological Proliferation in the Breast with Special Reference to Cystic Disease. Arch. Path., **33** (1942): 573-588.
- Innes, J. R. M., Seibold, H. R., and Arentzen, W. P.: The Pathology of Bovine Mastitis Caused by *Cryptococcus Neoformans*. Amer. Jour. Vet. Res., **13** (1952): 469-475.
- Jaskowsky: Über die Milchdrüse der Menschen und Tiere. Sitzungsbericht der naturw.-math. Klasse der Akad. d. Wissensch. zu Krakau, **7** (1880). Original not seen. Cited by Lenfers (1907).
- Jasper, D. E., Kanegis, L. A. and Weirether, F. J.: An Unusual Structure Associated with Bovine Necrotic Mastitis. Corn. Vet. **36** (1946): 268-276.
- Joest und Steck: Zeitschr. f. Infektionskrankh., **25** (1924): 21-44. Original not seen. Cited by McFadyean (1930).
- Johnston, T.: The Anatomical and Experimental Study of the Teat of the Cow with Particular Reference to Streptococcal Mastitis. Jour. Comp. Path. and Ther., **51** (1938): 69-77.
- Jorgensen, G. E.: Acute Parenchymatous Mastitis with Special Reference to Etiology and Pathology. Jour. Amer. Vet. Med. Assoc., **64** (1924): 699-704.
- Jorgensen, L.: Mastitis Fremkaldt af Blandingsinfektion med *Bacterium pyogenes* og Anaerobie Mikrokokker. Mannedsskrift for Dyrlaeger, **49** (1937): 8-129.
- Jorgensen, L.: Personal Communication. (1950).
- Jungherr, E. L.: Bovine Leptospirosis. Jour. Amer. Vet. Med. Assoc., **105** (1944): 276-281.

- Kaeppli, F.: Über Zitzen und Zisternenverhältnisse der Haussäugetiere. Inaugural Dissertation, Zurich (1918).
- Kamm, M.: Über den histologischen Bau der Rinder und Ziegenzitze. Inaugural Dissertation, Bern (1925).
- Kehrer: Zur Morphologie des Milchkaseins. Arch. F. Gynäkologie (1871). Original not seen. Cited by Lenfers (1907).
- Kitt, T.: Ueber eine durch Impfung hervorgerufene Euterentzündung der Kuh. Deut. Zeitsch. f. Tiermed. u. vergl. Path., **7** (1882): 303-307.
- Kitt, T.: Untersuchungen über die verschiedenen Formen der Euterentzündungen. Deut. Zeitsch. f. Tiermed. u. vergl. Path., **12** (1886): 13.
- Kitt, T.: Grundriss der pathologischen Anatomie für Tierärzte. Ferdinand Enke, Stuttgart (1931): 308-315.
- Kolessnikow, N.: Die Histologie der Milchdrüsen der Kuh und die pathologisch-anatomischen Veränderungen derselben bei der Perlsucht. Arch. f. patholog. Anatomie u. Physiologie, **70** (1877): 531-546.
- Kwong, F. J.: A Histological Study of the Mammary Gland of the Cow During Pregnancy. Jour. Amer. Vet. Med. Assoc., **94** (1940): 36-40.
- Langer, C.: Artikel "Milchdrüse" in Stricker's Handbuch, **1** (1871): 672. Original not seen. Cited by Lenfers (1907).
- Leblanc: Les maladies des mammelles chez les animaux domestiques. Paris (1901). Original not seen. Cited by Zobel (1902).
- Lenfers, P.: Zur Histologie der Milchdrüse des Rindes. Zeitsch. f. Fleisch u. Milchhyg., **17** (1907): 340-350, 383-390, 424-429.
- Little, R. B. and Baker, J. A.: Leptospirosis in Cattle. Jour. Amer. Vet. Med. Assoc., **116** (1950): 105-110.
- Little, R. G., Beck, J. D. and McGahan, J. V.: An Outbreak of Bovine Leptospirosis. Vet. Med., **45** (1950): 104-110.
- Lohse, E.: Histologische Untersuchungen über die streptokokken Mastitis des Rindes. Inaugural Dissertation, Leipzig (1933).
- Lübke, A.: Untersuchungen an einer latent infizierten, mit der Milch Bangbakterien ausscheidenden Kuh. Arch. f. wissenschaft. u. prakt. Tierheilk., **67** (1934): 436-452.
- Lucet: Sur la nature infectieuse der mammites chez la vache. Rec. de Med. vet. publ. à l'Ecole d'Alfort, (1889): 423.
- Lund, L.: Pathologische Histologie der Haustiere. M. and H. Schaper, Hannover (1931): 312-328.
- Maas, W.: Inaugural Dissertation, Berlin (1932). Original not seen. Cited by Munch-Petersen (1938).
- MacLeod, Patricia, and Anderson, E. O.: A Study of the Cell Counts of Milk from Healthy Cows. Storrs Agric. Exp. Sta. Bull. No. 290. (1952).
- Mankowski, H.: Der histologische Bau des Strichkanals der Kuhzitze. Polnisch. Arch. biol. med. Wissenschaft, **2** (1903-1904): 149-157.
- Martin, P.: Lehrbuch der Anatomie der Haustiere. **1**, Schichardt und Ebner, Stuttgart (1902). Original not seen. Cited by Lenfers (1907).
- Mathis: Sur la mammité parenchymateuse de la vache. Rev. vet., Toulouse (1885): 239. Original not seen. Cited by Zobel (1902).
- Maximow, A. A. and Bloom, W.: A Textbook of Histology. W. B. Saunders Company, Philadelphia and London (1938): 564-572.
- McFadyean, J.: The Corpora Amylacea of the Mammary Gland of the Cow. Jour. Comp. Path. and Ther., **43** (1930): 291-300.
- Michaelis: Beiträge zur Kenntnis der Milchsekretion. Arch. f. mikrosk. Anat. u. Entwicklungsgeschichte, **51** (1818): 711.
- Miller, W. T.: Bovine Mastitis. North Amer. Vet., **17** (1936): 32-41.
- Moore, R. A.: A Textbook of Pathology. W. B. Saunders Company, Philadelphia and London (1944): 1161-1162.
- Morrill, C. C.: A Histopathological Study of the Bovine Udder. Corn. Vet., **23** (1938): 196-206 and Thesis for Master of Science, Michigan State College (1935).
- Munch-Petersen, E.: Bovine Mastitis. Charles Burrell, Surrey (1938).
- Murphy, J. N.: The Genesis of Bovine Udder Infection and Mastitis. Proc. 49th Ann. Meeting, U. S. Livestock Sanitary Assoc. (1945): 30-43.
- Nieberle, K. and Cohrs, P.: Lehrbuch der speziellen pathologischen Anatomie der Haustiere. Gustave Fischer, Jena (1931): 578-588.
- Niven, C. F., Smiley, K. L. and Sherman, J. M.: Jour. Bact., **43** (1942): 651. Original not seen. Cited by Plastringe and Bryan (1946).
- Nocard and Mollereau: Sur une mammité contagieuse des vaches laitières. Ann. Inst. Past., **1** (1885). Original not seen. Cited by Stark (1903).

- Ohlen, R.: Experimental diplokokk-juverinflammation hos ko. Skand. Vet. Tidskr., **24** (1934): 116-130.
- Olafson, P.: Report of the Proc. 1st Ann. Meet. Northeast Mastitis Council (1948).
- Ottolenghi: Zur Histologie der tätigen Milchdrüse. Arch. f. Mikr. Anat., **58** (1901): 581.
- Palmer, C. C., Kakavas, J. C. and Hay, J. R.: Studies on Bovine Mastitis. Mastitis in Heifers. Amer. Jour. Vet. Res., **2** (1941): 18-34.
- Parr, L. W.: Coliform Bacteria. Bact. Revs., **3** (1939): 1-48.
- Pattison, I. H.: Studies on Experimental Streptococcal Mastitis. V. Histological Findings in Experimental Streptococcal Mastitis in the Goat. Jour. Comp. Path. and Ther., **61** (1951): 71-78.
- Pattison, I. H.: Studies on Experimental Streptococcal Mastitis. VI. Histological Examination of the Teats of Affected Goats. Jour. Comp. Path. and Ther., **62** (1952): 1-5.
- Pattison, I. H.: Personal Communication (1953).
- Pattison, I. H.: and Holman, H. H.: Studies on Experimental Streptococcal Mastitis. IV. The Disease Caused by Inoculation of *Streptococcus Agalactiae* Strain S13 into the Teat Canal of Goats. Jour. Comp. Path. and Ther., **61** (1951): 26-37.
- Pedersen, H. O.: Histologiske Undersøgelser over det normale og inficerede Kuieyver. Skand. Vet. Tidskr., **23** (1933): 603-624.
- Petersen, E. H., Hastings, E. G. and Hadley, F. B.: The Pathology of Nonspecific Mastitis and Consideration of Possible Etiological Agents. Corn. Vet., **28** (1938): 307-323.
- Plastringe, W. N., Anderson, E. O., Brigham, C. D., and Spaulding, E. H.: The Streptococci of Chronic Bovine Mastitis. Storrs Agric. Exp. Sta. Bul. No. 195 (1934).
- Plastringe, W. N., Anderson, E. O., and Seremet, J. S.: Infectious Bovine Mastitis. Storrs Agric. Exp. Sta. Bul. No. 224 (1938).
- Plastringe, W. N. and Bryan, C. S.: Diagnosis of Mastitis. II. Examination of Udder Secretion. Chap. IV. From: Little, R. B. and Plastringe, W. N.: Bovine Mastitis. McGraw-Hill Book Co., New York and London (1946): 137.
- Plastringe, W. N. and Hale, H. H.: Mastitis Control in Connecticut. Corn. Vet., **38** (1948): 292.
- Plastringe, W. N.: Personal Communication. (1951).
- Pounden, W. D., Amberson, J. M., and Jaeger, R. F.: A Severe Mastitis Problem Associated with *Cryptococcus Neoformans* in a Large Dairy Herd. Amer. Jour. Vet. Res., **13** (1952): 121-128.
- Rackow, H. G.: Bau und Entstehung der stenosierenden Ringfalten in der Zitze des Rindes. Deut. tierärztl. Wchnsch., **49** (1941): 569.
- Rast: Der gelbe Galt. Schweiz. Arch. Tierheilk., **13** (1854): 289. Original not seen. Cited by Stark (1903).
- Rauber, A.: Remarks on the Finer Structure of the Mammary Gland. (Title trans.) Schmidt's Jahrbücher, 182 (1879): 7. Original not seen.
- Rheinhardt: Ueber die Entstehung der Kornchenzellen. Virch. Arch.: **1** (1847). Original not seen. Cited by Lenfers (1907).
- Richardson, K. C.: Structural Features of Mammary Tissues. Brit. Med. Bul., **5** (1947-48): 123-129.
- Richardson, K. C.: Contractile Tissues in the Mammary Gland, with Special Reference to Myoepithelium in the Goat. Pro. Royal Society of London, **136** (1949-50): 30-45.
- Riederer: Ueber den Bau der Papillae mammae des Rindes. Arch. f. Wissensch. u. prakt. Tierheilk., **29** (1903): 593-625.
- Rienhoff, E.: Berl. tierärztl. Wchnsch., **45** (1929): 746. Original not seen. Cited by Munch-Petersen (1938).
- Rubeli, O.: On the Anatomical Relationship of the Cow's Udder and its Physiological and Pathological Significance. (Title trans.) Schweiz. Arch. f. Tierheilk., **58** (1916): 357. Original not seen. Cited by Turner (1933).
- Runnells, R. A., Animal Pathology. Iowa State College Press, Ames (1946): 442-449.
- Runnells, R. A. and Huddleson, I. F.: The Nature of *Bacterium abortus* Infection in the Udder of the Bovine. Corn. Vet., **15** (1925): 376-392.
- Salle, A. J.: Fundamental Principles of Bacteriology. 3rd Ed., McGraw-Hill Book Co., New York, Toronto, and London (1948): 486.
- Schlegel, H.: Münch. tierärztl. Wchnsch., **84** (1933): 301. Original not seen. Cited by Munch-Petersen (1938).
- Schlösser, C.: Zur vergleichenden pathologischen Anatomie und Aetiologie der Mastitis. Deut. Zeitsch. f. Tier med. u. vergl. Path., **9** (1883): 260-276.
- Seifried, O.: Lehrgang der Histopathologie. Julius Springer, Berlin (1934): 125-126.

- Sholl, L. B., and Torrey, J. P.: Contribution to the Bacteriology and Pathology of the Bovine Udder. Mich. State Coll. Agric. Exp. Sta. Tech. Bul. No. 110 (1931).
- Sholl, L. B.: Pathology of Mastitis. Chap. III. From: Little, R. B. and Plastringe, W. N.: Bovine Mastitis, McGraw-Hill Book Co., Inc. New York and London (1946): 99-110.
- Simon: Ueber Bakterien am und im Kuheuter. Dissertation, Erlangen (1898), reviewed in Deut. tierärztl. Wchnsch., (1900): 363.
- Sisson, S.: The Anatomy of the Domestic Animals. 2nd Ed., W. B. Saunders Company, Philadelphia and London (1914): 729.
- Smith, H. A.: Two Cases of Actinomycotic Mastitis. Jour. Amer. Vet. Med. Assoc., **84** (1934): 635-645.
- Smith, T., Orcutt, H. L., and Little, R. B.: The Source of Agglutinins in the Milk of Cows. Jour. Exp. Med., **37** (1923): 153.
- Sobotta, J., and Piersol, W. N.: Textbook of Human Histology and Microscopic Anatomy. G. E. Stechert and Co., New York (1930): 309-310.
- Spencer, G. R.: The Significance of Hypersensitivity in Bovine Mastitis as Determined by a Study of its Pathogenesis. Thesis, Univ. of Wisc. (1949).
- Spencer, G. R., and Lillesand, J. E.: An Acute Disease Probably Associated with Leptospira. Vet. Sci. News, Univ. of Wisc., **4** (1950): 14-15.
- Staack, E.: Ueber die Veränderungen an den supramammären Lymphknoten bei der chronischen Streptokokkenmastitis (gelber Galt). Inaugural Dissertation, Leipzig (1933).
- Stark, H.: Beiträge zur pathologischen Anatomie der Agalactia catarrhalis contagiosa (Kitt). Inaugural Dissertation, Zurich (1903).
- Steck, W.: Untersuchungen über die bakterielle Besiedlung normaler Kuheuter. Inaugural Dissertation, Luzern (1921).
- Steck, W.: Untersuchungen über den Sitz der Keime bei Streptokokken und Pyogenemastitis des Rindes. Inaugural Dissertation Hannover (1931).
- Taylor, N. B.: Stedman's Medical Dictionary. 17th Ed., Williams and Wilkins Co., Baltimore (1949).
- Trautmann, A. and Fiebig, J.: Lehrbuch der Histologie und vergleichenden mikroskopischen Anatomie der Haussäugetiere. Paul Parey, Berlin (1931): 296-301.
- Tucker, E. W.: Mycobacteria as a Cause of Mastitis. Report of the Proc. 6th Ann. Meet. Northeast Mastitis Council (1953).
- Turner, C. W.: The Anatomy of the Mammary Gland of Domestic and Laboratory Animals. Univ. of Missouri (1933).
- Turner, C. W.: Physiology of Milk Secretion. Chap. II. From: Little and Plastringe: Bovine Mastitis, McGraw-Hill Book Company, Inc., New York and London (1946): 63-98.
- Tweed, R. L.: The Relation of High Cellular Counts to *Bact. abortus* Infection of the Udder. Mich. Agric. Exp. Sta. Tech. Bul. No. 61 (1923).
- Van der Linde: Die Gewebsveränderungen im Euter bei *Galactophoritis sporadica* der Kuh. Arch. f. wissensch. u. prakt. Tierheilk., **32** (1906): 349-356.
- Venzke, C. E.: A Histological Study of the Teat and Gland Cistern of the Bovine Mammary Gland. Jour. Amer. Med. Assoc., **96** (1940): 170-175.
- Webster, N.: Webster's Collegiate Dictionary. 5th Ed., G. and C. Merriam Co., Springfield, Mass. (1944).
- Winckler, F. N.: Arch. Gynäk., **11** (1877): 294-303. Original not seen. Cited by Emmerson (1946).
- Wirz, O.: Das Hohlraumssystem der Milchdrüse beim Rind. Inaugural Dissertation, Bern (1913).
- Wulff, C. A.: Experiments on Milk Production, Ind. Agric. Exp. Sta. Bul. No. 24 (1889).
- Zobel, K.: Beiträge zur Kenntnis der anatomischen Veränderungen der Milchdrüsen unserer Haustiere. Inaugural Dissertation, Bern (1902).
- Zimmermann, A.: On the Starch-like Structures in the Milk Glands of Cattle. (Title trans.) Zeitschr. f. Fleisch u. Milchhyg., **19** (1909): 425. Original not seen. Cited by Turner (1933).
- Zschokke, M.: Die Entwicklung des Ausführungsgangsystems der Milchdrüse. Inaugural Dissertation, Zurich (1919).
- Zschokke, E., and Strebel, M.: Weitere Untersuchungen über den gelben Galt. Schweiz. Tierheilk., **39** (1897): 145-167.
- Zwart, S. G.: Beiträge zur Anatomie und Physiologie der Milchdrüse des Rindes. Inaugural Dissertation, Bern (1911).



**Table I**  
*Corpora amylacea in relation to disease and lactation*

Platridge & Hale (1948) Groupings	Days Lactating											
	30	60	90	120	150	180	210	240	270	300	330	Over
I	2/7	1/2	1/2	0/1	1/3	2/3	1/2	4/5	0/1	0/2	0/0	4/9
II	2/8	0/0	1/2	0/1	1/1	1/1	4/4	2/3	0/0	3/4	1/1	6/10
IIIc	2/3	3/3	0/3	0/0	1/1	1/2	0/0	1/1	0/1	0/1	1/1	1/1
IIIcp	1/1	0/0	0/0	0/0	0/0	0/0	0/0	0/0	0/0	0/0	0/0	0/0
IV & V	1/3	1/2	0/0	1/2	0/1	0/0	0/0	0/0	0/0	1/1	0/0	4/4
Silver Oxide	1/2	0/1	0/0	0/1	0/2	0/2	0/0	0/0	0/0	0/0	0/0	0/1

Legend: Numerator indicates number of udders with corpora amylacea.  
Denominator indicates number of udders examined.

**Table 2**  
*Histopathologic lesions in normal udders*

Grade of Histologic Mastitis Observed					Leukocytes per ml. (in millions) on day slaughtered				Remarks
RF	RH	LF	LH		RF	RH	LF	LH	
1	—	—	I	—	0.37	0.72	0.37	0.25	
2	I	—	I	I	0.25	0.13	0.50	0.25	Staphylococcus in RF
3	—	I	—	I	0.03	0.78	0.28	0.03	" " RH
4	—	I	II	I	0.30	0.44	2.00	0.34	Coliform in LF
5	I	I	I	I	0.04	0.09	0.09	0.06	
6	—	I	—	—	0.56	0.22	0.06	0.22	
7	I	—	I	I	0.37	0.72	0.37	0.25	

Legend: — Indicates quarter negative bacteriologically and histologically.  
Roman numeral indicates grade of mastitis as I (slight).

**Table 3**

*The presence of heterophils in quarters of coliform mastitis*

	Days Lactating	Age in Years	Duration of Infection in Months	Grade of Mastitis	Granulocytes in Coliform Quarters
1	3	3.0	1/10	III	1+
2	30	—	1	III	1+
3	30	2.5	12	III	1+
4	30	8.5	1/2	III	0
5	60	3.0	2	II	1+
6	194	6.7	12	III	1+
7	210	5.1	—	II	0
8	240	11.6	24	II	0
9	252	6.0	2	II	4+
10	360	3.0	—	II	0

Legend: 0-4+ = no heterophils to masses of heterophils.

**Table 4**

*Silver oxide in the udder and supramammary lymph nodes*

	Time Elapsed between Treatment and Slaughter	Silver Oxide in Udder Tissue	Silver Oxide in Supramammary Lymph Nodes
1	2 weeks	+	—
2	3 weeks	+	—
3	20 weeks	+	+
4	28 weeks	+	—
5	59 weeks	+	+
6	60 weeks	+	—
7	60 weeks	+	—
8	194 weeks	+	+

Table 5

*The supramammary lymph nodes of normal udders*

	Days Lactating	Age in Years	Left Lymph Node	Right Lymph Node	Measurement of Lymph Nodes in Centimeters	
					Left	Right
1	0	2.8	H 1+	H 1+	—	—
2	7	6.0	N	N	—	—
3	20	2.1	S 2+	S 2+	6 x 4 x 2	5.5 x 3 x 1
4	33	3.0	S 2+	S 2+	9 x 5 x 2	7 x 5 x 2
5	60	3.0	S 2+	S 2+	—	3 x 2 x 2
6	150	10.0	S 2+	S 3+	—	—
7	153	3.1	S 3+	N	9 x 5 x 1.5	7 x 6 x 1.5
8	180	6.0	N	N	4 x 2 x 1.5	6 x 4 x 1
9	240	4.7	H 1+	—	6 x 2 x 1.5	6 x 1.5 x 1
10	420	4.0	S 2+	S 2+	—	—
11	480	4.1	N	Edema 3+	12 x 5 x 4	12 x 6 x 4
					9 x 2 x 2	10 x 5 x 2
					9 x 6 x 1.5	4 x 2 x 2
					9 x 6 x 1.5	9 x 6 x 1.5
					7 x 3.5 x 1.5	6 x 3 x 1
					Av. 7.9 x 3.9 x 1.9	6.7 x 3.9 x 1.9
					±2.4 ±1.4 ±0.9	±2.6 ±1.7 ±0.9

Legend: CH = Cortical hyperplasia.

H = Heterophils.

N = Normal.

1+ to 4+ = Indicates degree from slight to marked.

S = Sclerosis.

— = No observation made.

Table 6

*The supramammary lymph nodes of udders infected by coliform organisms*

	Days Lactating	Age in Years	Duration of Infection in Months Left Side/Right Side of Udder	Left Lymph Node	Right Lymph Node	Measurement of Lymph Nodes in Centimeters	
						Left	Right
1	3	3	1/10 / 1/10	Edema 1+ H 1+	Edema 1+	7 x 5 x 3	10 x 6 x 3
2	30	2.5	1/1	S 1+	—	14 x 6 x 3	—
3	194	6.7	12/5	N	N	9 x 8 x 1	10.5 x 7 x 1.5 4 x 2.5 x 2
4	210	5	6/0	S 2+ H 1+	S 1+ H 1+	—	12 x 10 x 2.5 6 x 5 x 2
5	240	11.6	24/24	S 2+	S 2+	15 x 9 x 3 8 x 4 x 3.5	14 x 10 x 3
6	360	?	—	S 3+	S 3+	6 x 2 x 1.5	—
						Av. 9.8 x 5.6 x 2.5 ±3.8 ±2.6 ±1.0	9.2 x 6.8 x 2.3 ±3.7 ±2.9 ±1.7

Legend: See Table 10.



Table 7

*The supramammary lymph nodes of udders infected by staphylococci*

	Days Lactating	Age in Years	Duration of Infection in Months Left Side/Right Side of Udder	Left Lymph Node	Right Lymph Node	Measurement of Lymph Nodes in Centimeters	
						Left	Right
57	1	8.3	0/4	S 3+	H 3+	—	—
				CH 4+	S 3+		
	3	64	3.0	24/24	CH 4+	9 x 5 x 2	
	2	40	6.3	1/1	S 1+	7 x 5 x 2	12 x 7 x 3
	4	120	5	12/12	CH 2+	7 x 5 x 1.5	9 x 6 x 2.2
				S 1+	S 1+	15 x 10 x 3	12 x 9 x 2.5
	5	152	5.0	18/18	Acute Lymphadenitis	—	—
	6	208	4.9	12/12	Edema 1+	9.5 x 7 x 1.5	9.5 x 6 x 1.3
				H 1+	Acute Lymphadenitis		5 x 2.5 x 2
	7	210	4.2	6/6	S 1+	6 x 6 x 2	8.5 x 7.5 x 1.5
	8	228	6.1	24/24	N	11 x 8 x 1.5	9.5 x 9.5 x 1.5
				CH 2+	H 1+		
	9	229	2.6	1/1	CH 2+	7.5 x 7 x 2.5	8 x 5 x 2.5
				S 2+	S 2+		
	10	314	4.0	12/12	CH 1+	11 x 7 x 3	6 x 3 x 2
				S 2+	S 1+		
	11	330	4.0	1/6	H 1+	6 x 4 x 1.5	
	12	350	4.7	0/3	S 2+	3 x 2.5 x 1	5.5 x 5 x 1.5
				N	N	8.5 x 6 x 1.5	8.5 x 6 x 2
	13	370	4.2	10/10	H 1+	5 x 3 x 1.5	6 x 2 x 2
				S 2+	S 1+	6 x 4 x 1.5	6 x 5 x 1.5
	14	390	8.5	12/12	H 1+	7 x 4 x 1	
				Hemorrhages	H 2+	7 x 6 x 3	11.5 x 5 x 2
	15	420	7.5	1/1	S 4+	12 x 7 x 3	12 x 7 x 2
	16	442	6.8	0/12	S 1+	6 x 3 x 2	7 x 7 x 2.5
						Av. 7.9 x 5.6 x 1.9 ±2.9 ±1.9 ±0.7	8.5 x 5.8 x 2.0 ±2.5 ±2.0 ±0.5

Legend: See Table 10.

Table 8

*The supramammary lymph nodes of udder infected by Str. agalactiae*

	Days Lactating	Age in Years	Duration of Infection in Months Left Side/Right Side of Udder	Left Lymph Node	Right Lymph Node	Measurement of Lymph Nodes in Centimeters	
						Left	Right
1	—	—	—	H 1+ S 4+	S 3+	12 x 10 x 3	15 x 7 x 2
2	12	12.6	48/36	S 2+	S 2+	—	—
3	23	4.1	0/12	N	CH 1+	6 x 5 x 3	—
4	45	8.1	60/60	S 2+	S 2+	—	—
5	47	13.1	60/24	CH 1+ S 3+	S 3+	10 x 10 x 3	10 x 8 x 3 3 x 3 x 2.5
6	96	7.1	24/30	CH 1+ S 2+	CH 1+ S 3+	11 x 7 x 2.5	6 x 3 x 3 7.5 x 5.5 x 3
7	120	5.8	3/2	S 1+	S 1+	9 x 6 x 2	8 x 5 x 3
8	295	7.0	24/24	N	N	—	—
9	401	4.6	24/24	—	N	—	7 x 2.5 x 2
10	403	11.1	36/36	S 1+ Hemorrhages	S 1+ Hemorrhages	15 x 2 x 5 25 x 15 x 7	18 x 15 x 6 17 x 12 x 5
11	859	18.1	60/60	S 2+ Hemorrhages	S 2+ Hemorrhages	16 x 12 x 2.5 16 x 11 x 3	15 x 10 x 6 14 x 9 x 3
12	1000+	18.0	120/120	H 1+, S 3+	H 1+, S 3+	7 x 5 x 3	12 x 10 x 3
						Av. 12.7 x 8.3 x 3.4 ±5.6 ±5.2 ±1.5	11.0 x 7.5 x 3.5 ±3.9 ±3.8 ±1.4

Legend: See Table 10.

Table 9

*The supramammary lymph nodes of udders infected by other streptococci*

	Days Lactating	Age in Years	Duration of Infection in Months		Left Lymph Node	Right Lymph Node	Measurement of Lymph Nodes in Centimeters	
			Left Side/Right Side of Udder				Left	Right
1D	60	3.0	0/2	D	N	N	—	—
2U	143	7.9	9/0	U	H 1+	H 1+	—	—
					S 3+	S 3+	3.8 x 2.5 x 1	—
3U	172	7.1	12/24	U	S 3+	S 3+	6.4 x 2.5 x 1	5 x 3.2 x 2
4U	229	6.1	6/6	U	S 3+	S 3+	—	8 x 5 x 1.5
							6 x 3 x 1.5	
							5 x 3 x 2	8 x 5 x 3
5D	240	8.0	0/8	D	S 1+	S 3+	6 x 4 x 1.5	7 x 4 x 1.5
							4 x 3.5 x 2	4 x 3 x 2
6U	270	5.3	9/6	U	S 1+	S 2+	6 x 5 x 2	6 x 6 x 2
							9.5 x 7 x 1.5	
						S 1+	5 x 4 x 1	
7D	330	10.0	12/12	D	N	H 1+	3 x 2 x 1	1.4 x 10 x 2
8U	362	3.9	3/0	U	S 1+	N	6.5 x 7 x 1.5	8 x 6 x 2
9U	441	3.6	12/0	U	N	N	—	—
							Av. 5.6 x 4.0 x 1.5	7.5 x 5.3 x 2.0
							±1.7 ±1.7 ±0.4	±3.0 ±2.3 ±0.7

Legend: See Table 10

D = *Str. dysgalactiae*.

H = Heterophils.

N = Normal.

S = Sclerosis.

U = *Str. uberis*.

Table 10

*Analysis of variance of the supramammary lymph nodes in relation to hyperplasia*

Organism	Average Measurement in Centimeters of Both Left and Right Lymph Nodes		
	(1)	(2)	(3)
Normal .....	$7.18 \pm 2.53$	$3.88 \pm 1.51$	$1.86 \pm 0.83$
Coliforms .....	$9.62 \pm 1.13$	$6.20 \pm 0.84$	$2.41 \pm 0.41$
Staphylococci .....	$8.19 \pm 2.67$	$5.67 \pm 1.98$	$1.95 \pm 1.86$
Str. agalactiae ....	$17.9 \pm 5.0$	$7.82 \pm 4.4$	$3.43 \pm 1.40$
Other Streptococci .....	$6.01 \pm 3.31$	$4.51 \pm 2.0$	$1.68 \pm 0.5$
	$P < 0.001$	$P < 0.001$	$P < 0.001$



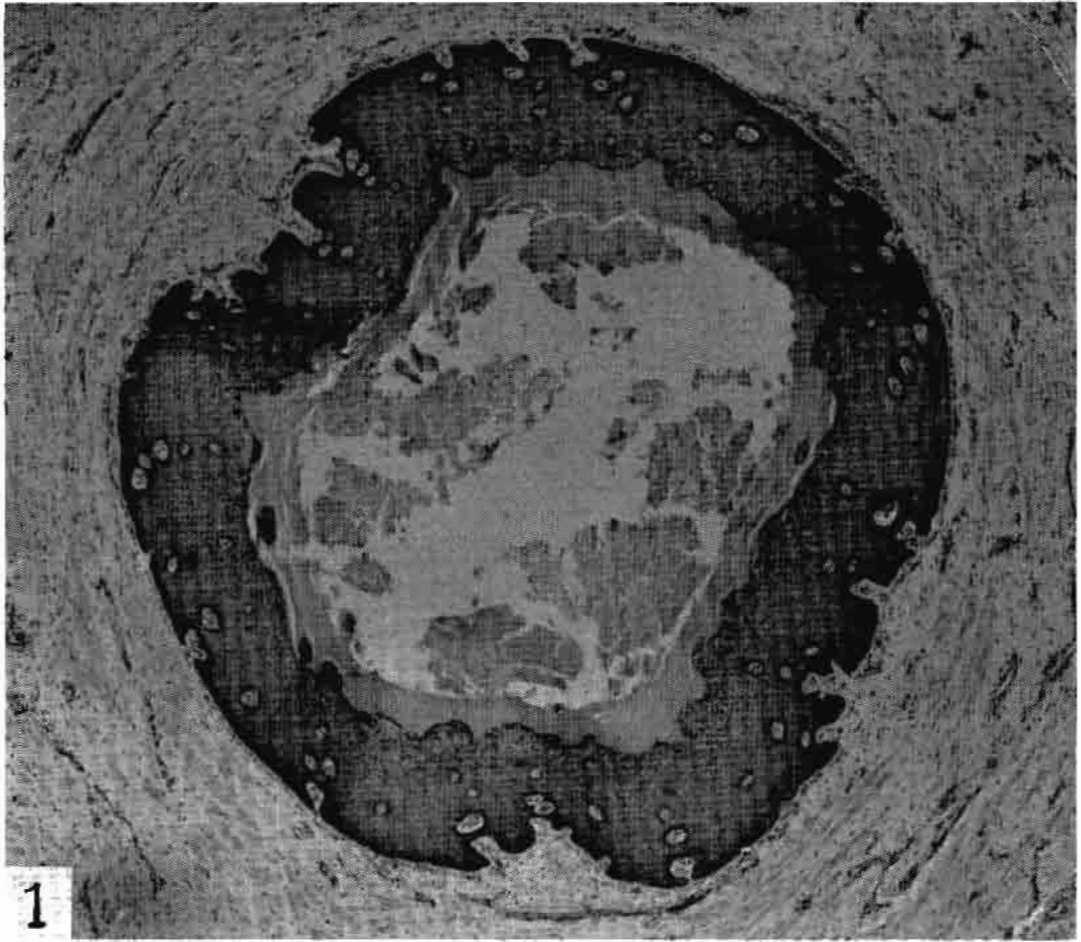


Fig. 1. Cross section of the teat canal from a two-year-old virgin heifer. Dermal papillae are seen as the large white islands in the epithelium. The sebaceous cells are barely visible as pin point light areas of the inner portions of the epithelium. HH Trios, 45X.

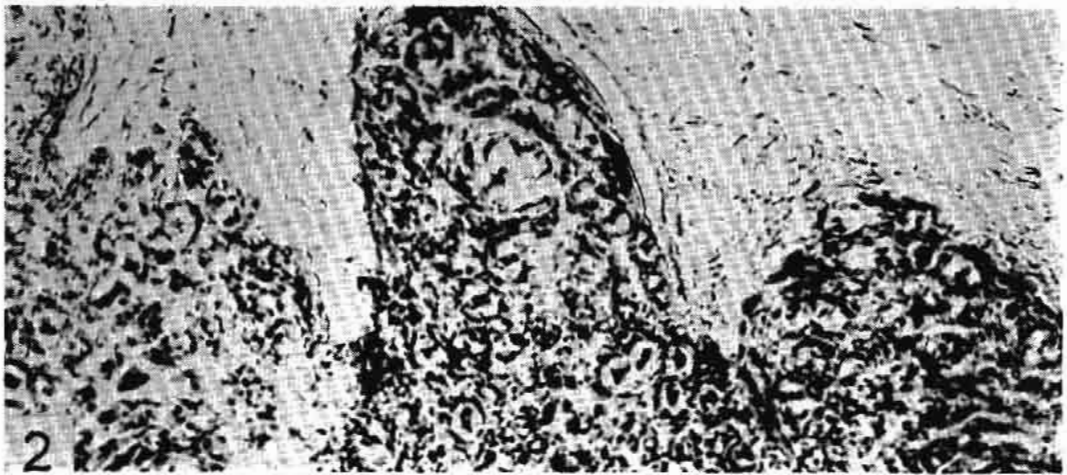

Fig. 2. Same section as Fig. 1, showing a dermal papilla in center bottom and several sebaceous cells in the center, which are seen as large clear cells. HH Trios, 290X.

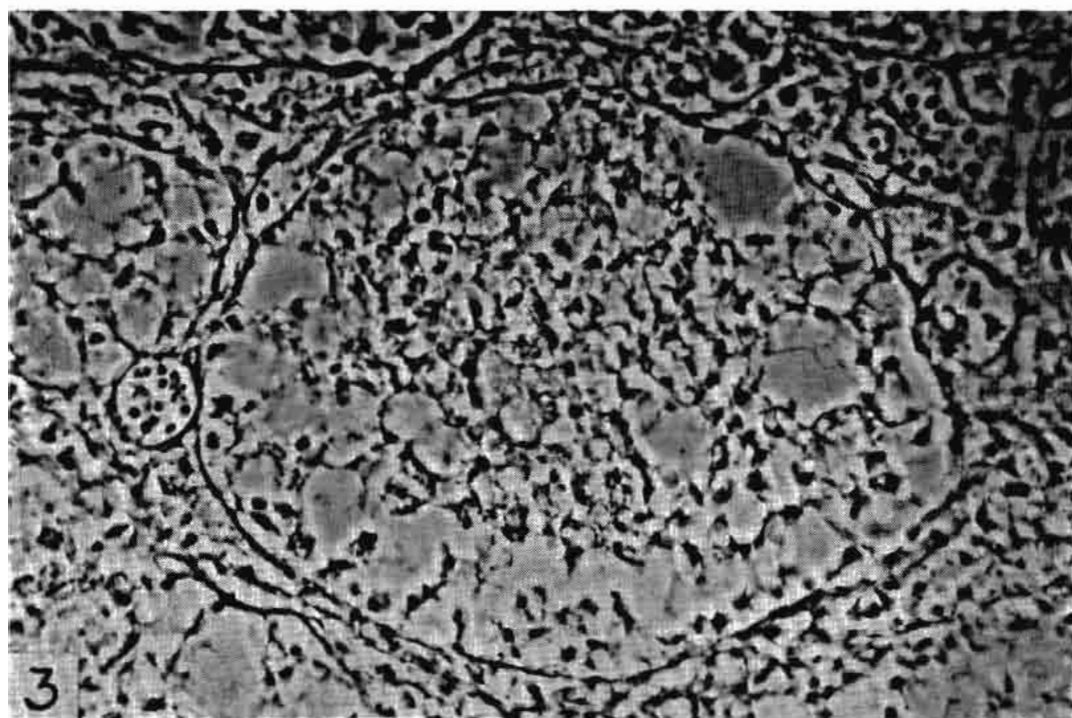


Fig. 3. Udder section from a six-year-old cow, 125 days lactation, showing a normal well defined basement membrane. The small circles in the equatorial plane on either side of the alveolus are capillaries. Phase microscope, 650X.

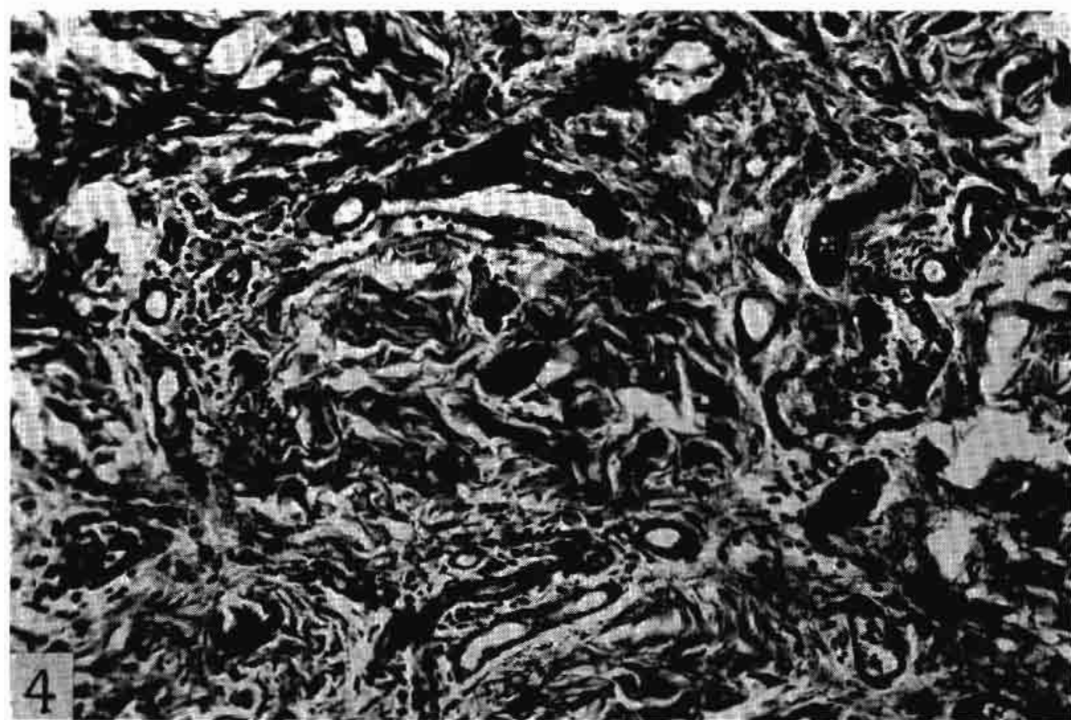


Fig. 4. Section of teat wall from a normal two-year-old virgin heifer showing perivascular lymphocytes. HH Trios, 180X.

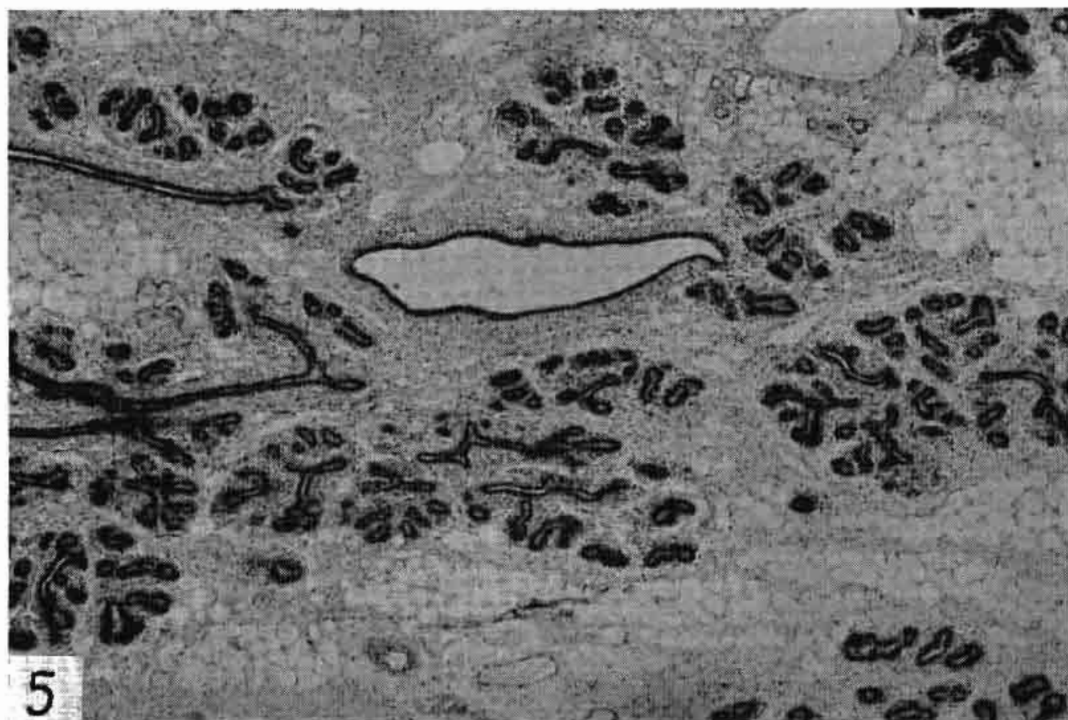

Fig. 5. Udder section from a normal yearling heifer showing ducts and chiefly fatty tissue. Closely surrounding the ducts is the specialized connective tissue. BHEY, 45X.

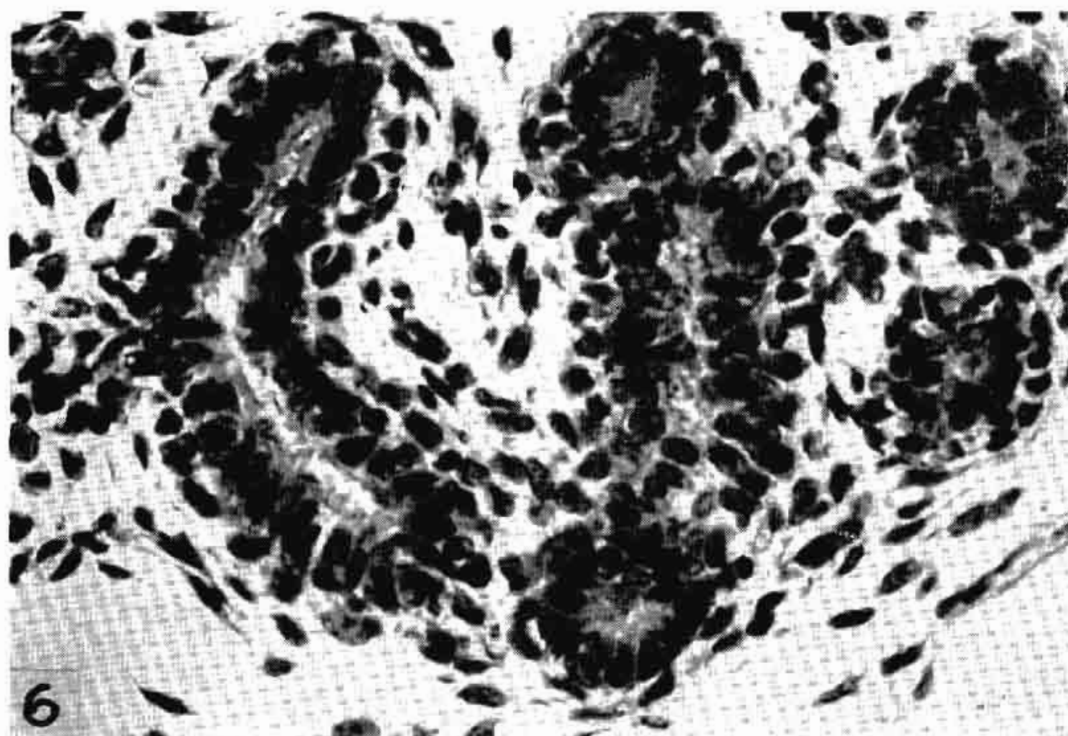


Fig. 6. Same section as Fig. 5, showing chiefly a single layer of epithelium in the ducts and the specialized connective tissue. H & E, 650X.

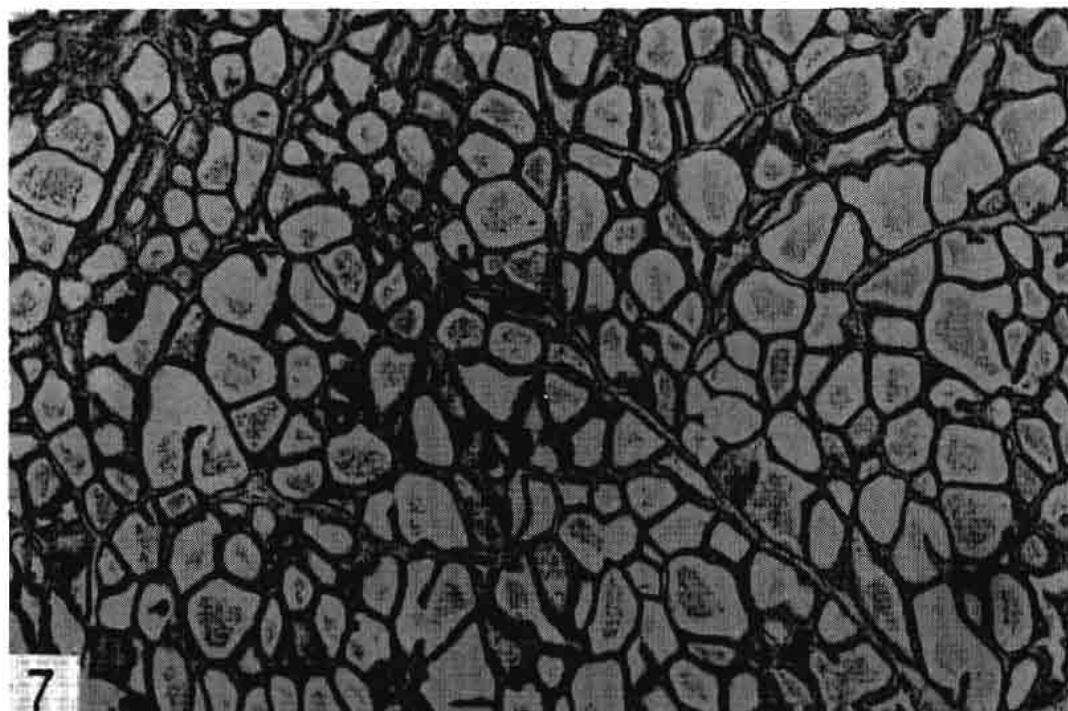


Fig. 7. Udder section from a normal two-year-old heifer, 20 days lactation showing empty alveoli as the normal secretion washed out during fixation. HH Trios, 45X.

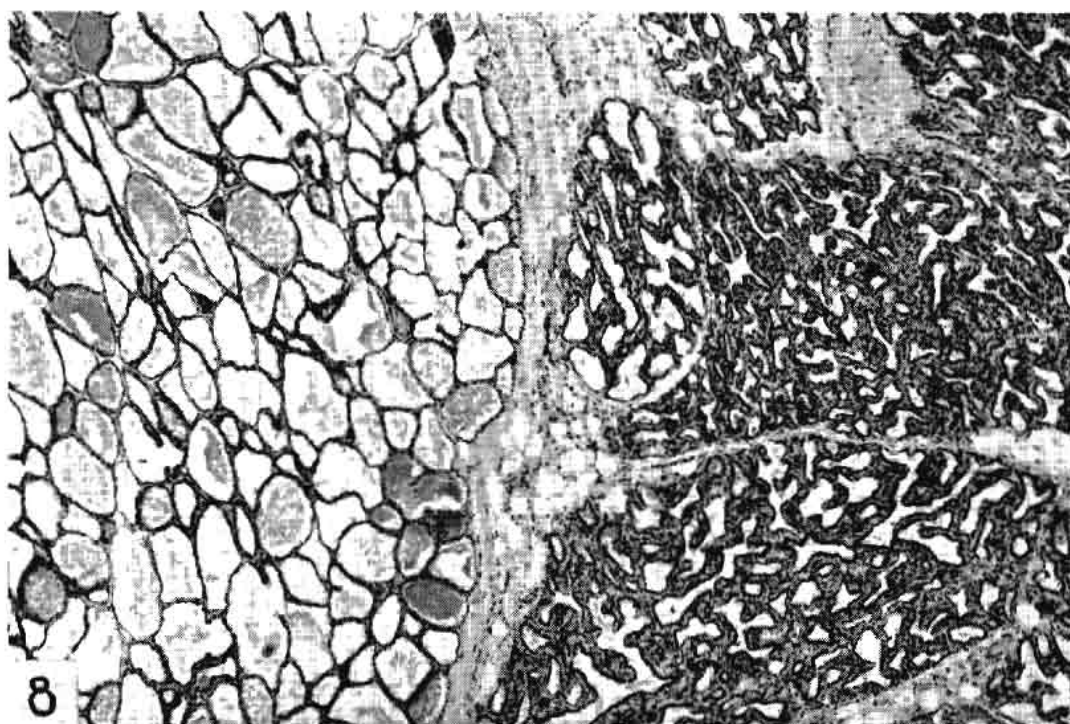


Fig. 8. Udder section from a two-year-old heifer, 30 days lactation, showing lobuli at left filled with milk as in Fig. 7. At the right the lobuli are non-functional with some interalveolar and intraductal proliferation. H & E, 45X.



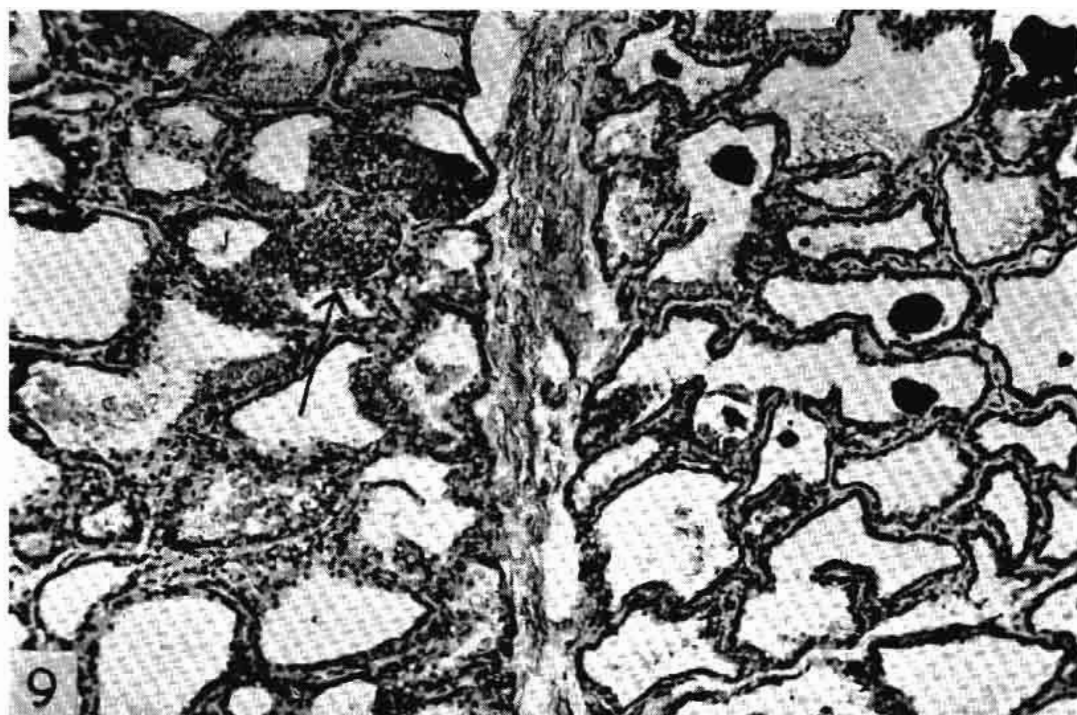


Fig. 9. Udder section from a normal four-year-old cow, 480 days continuous lactation, showing only slight involution and a tendency toward multi-layered alveolar epithelium (arrow). BHEY, 120X.

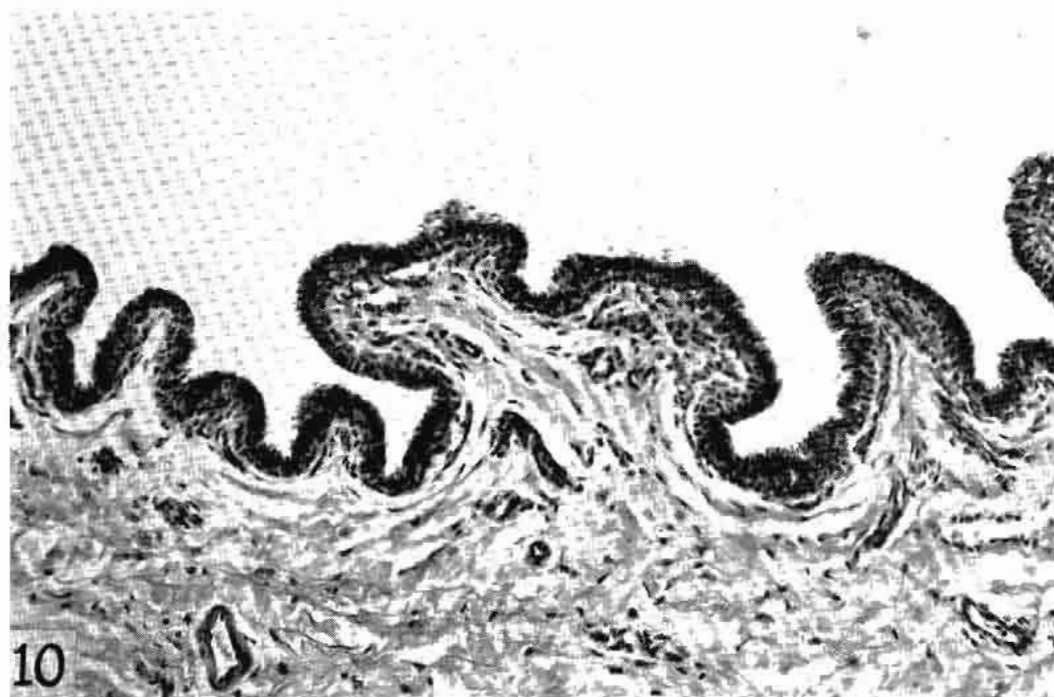

Fig. 10. Cisternal membrane from a two-year-old virgin heifer, showing a double layered lining epithelium (dark line) and a dense lamina propria (pale area). HH Trios, 180X.

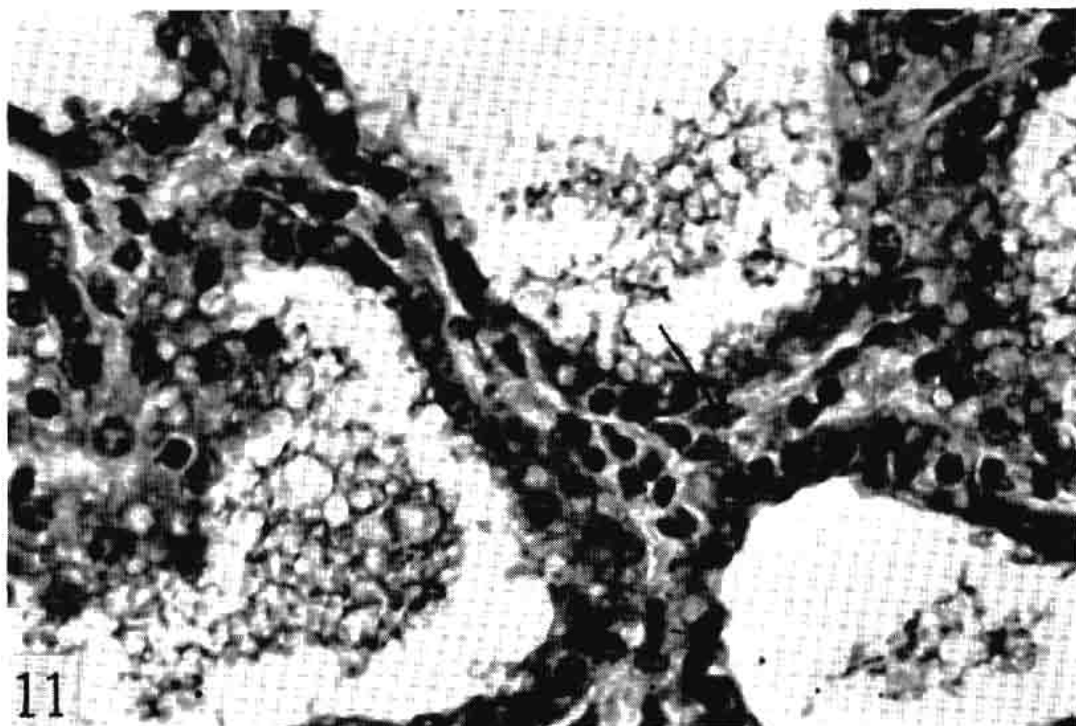


Fig. 11. Udder section from a normal four-year-old cow, 480 days continuous lactation, showing basket cells (arrow) and slight secretion in alveoli. BHEY, 650X.

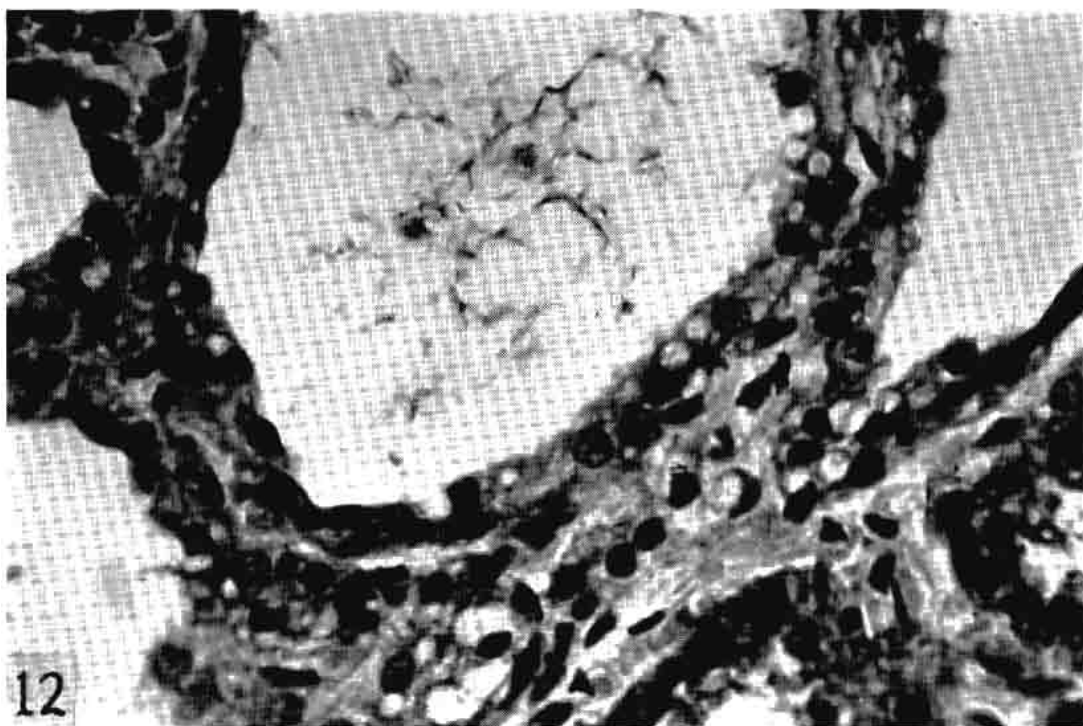


Fig. 12. Same section as Fig. 11. The interalveolar tissue is beginning to increase; early involution. BHEY, 650X.

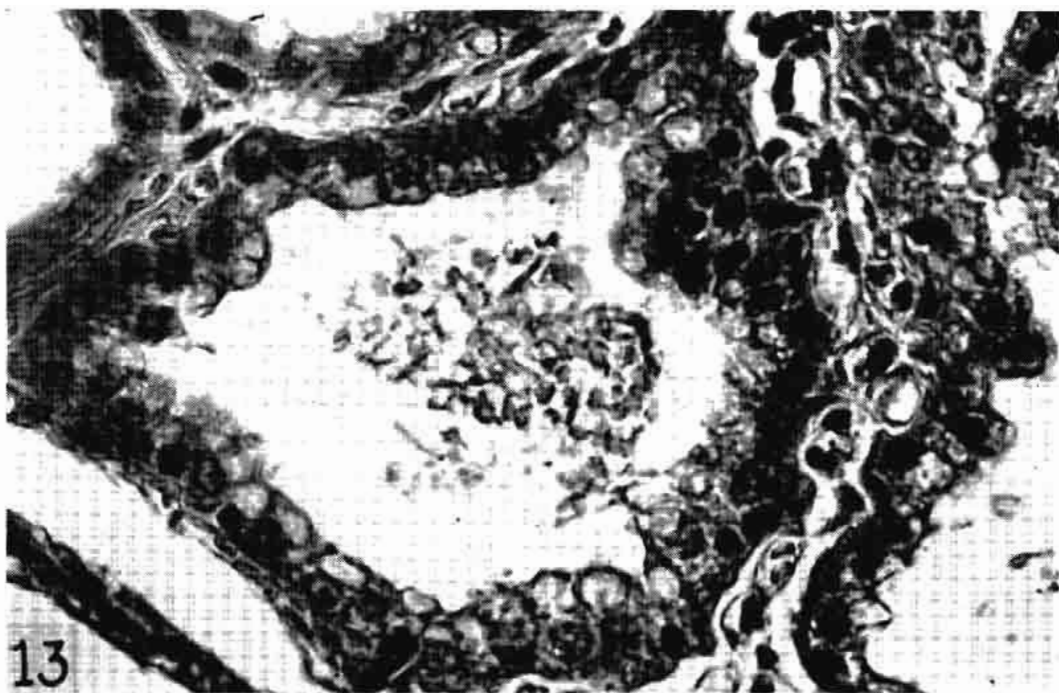


Fig. 13. Udder section from a normal two-year-old heifer, 20 days lactation, showing barely visible basement membrane and multi-layered epithelium at the right. Note similarity to Figs. 11 and 12, which were from an udder of 480 days lactation. HH Trios, 650X.

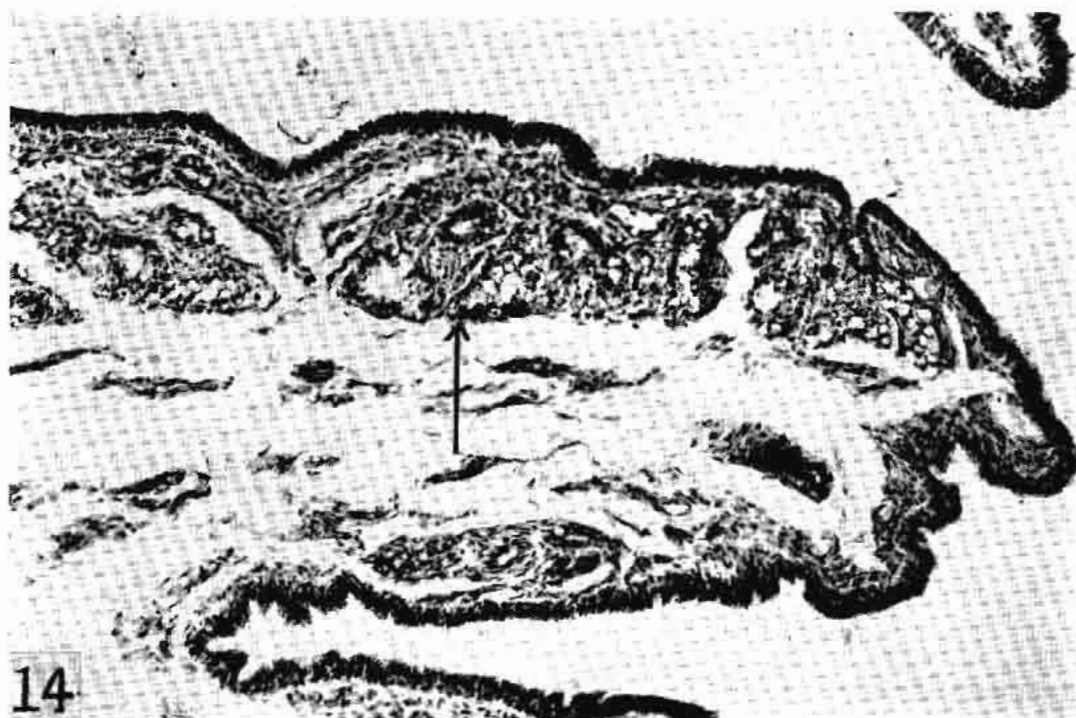


Fig. 14. Cisternal area of a normal two-year-old heifer, 20 days lactation, showing accessory glands (arrow). HH Trios, 90X.

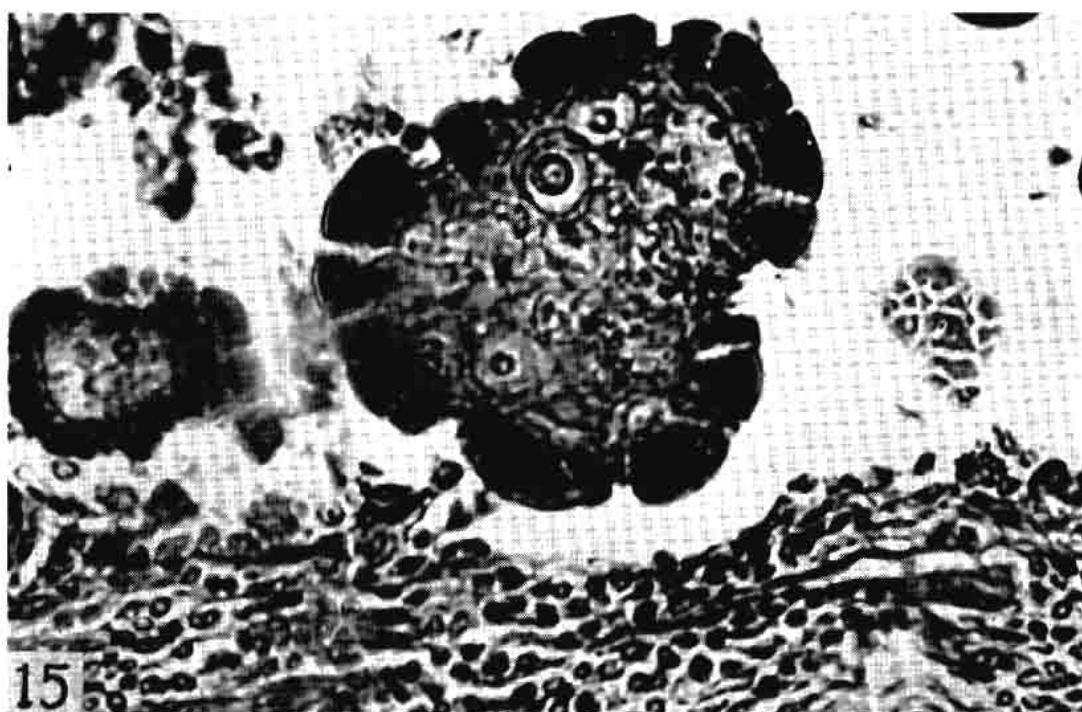


Fig. 15. Corpora amylacea in an alveolus of a normal three-year-old heifer, 360 days lactation, showing nuclei of epithelial cells visible within the concretions. HH Trios, 650X.




Fig. 16. Corpus amylaceum in center of cisternal membrane from a 15-year-old cow, 210 days lactation. The cisternal membrane is normal although the quarter was infected by *E. coli* and *Str. uberis* several times in the preceding nine years. HH Trios, 650X.



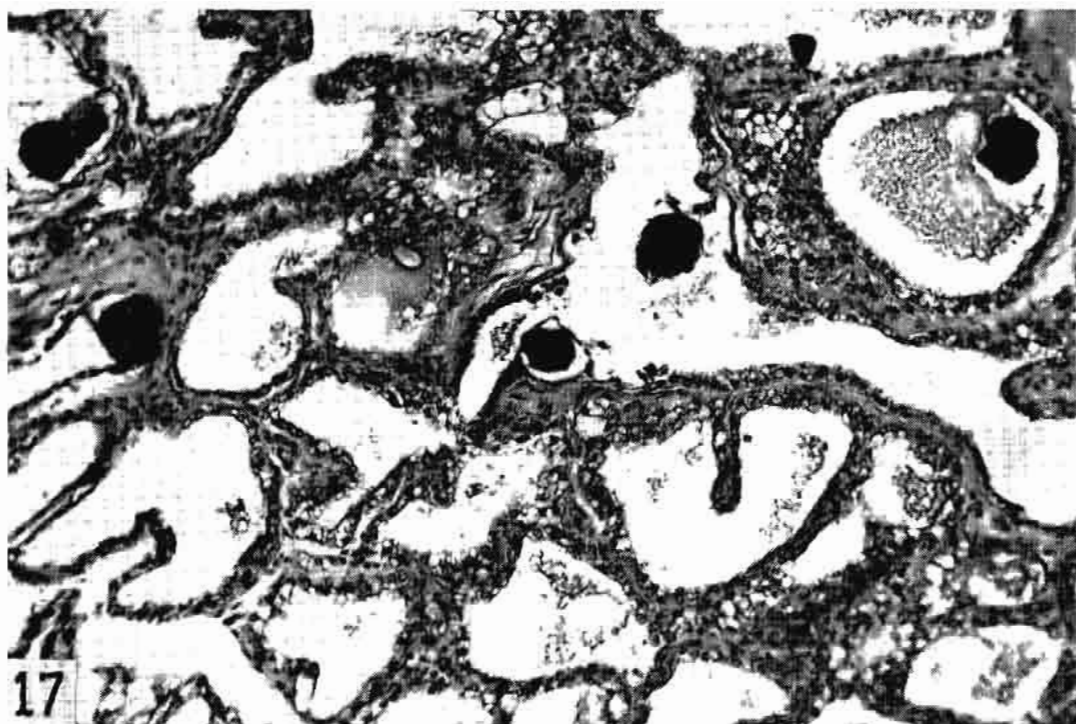


Fig. 17. Udder section from an aged cow of unknown history, showing solid corpora amylacea in almost completely functional alveoli. *Str. agalactiae* in milk secretion. HH Trios, 180X.

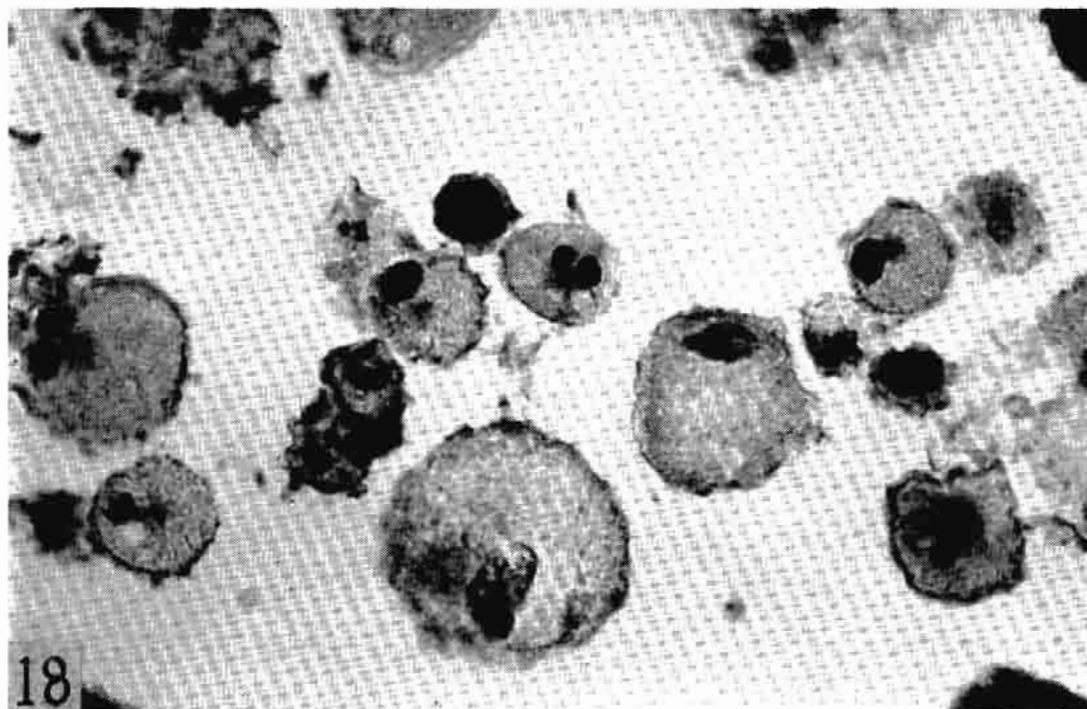


Fig. 18. Colostrum bodies in lumen of a large collecting duct of a three-year-old cow, 60 days lactation, showing definite nuclei. *Str. dysgalactiae* in secretion for 60 days. BHEY, 650X.

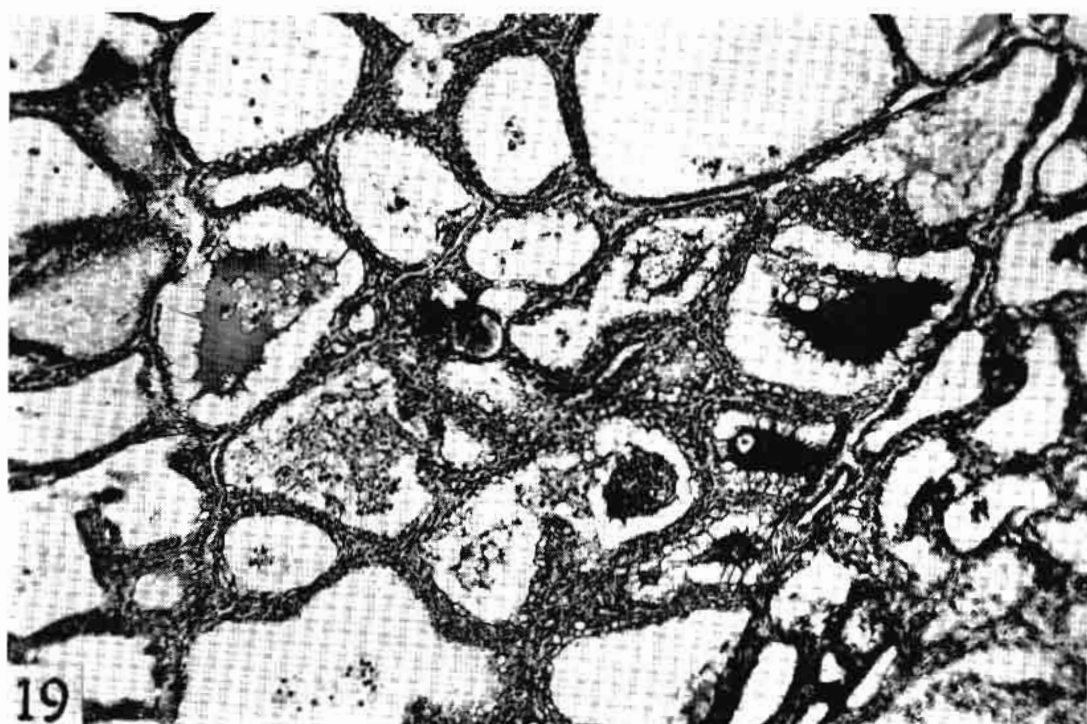

Fig. 19. Udder section from a six-year-old cow, 125 days lactation, showing milk clots with pseudopodia and a few heterophils, an early lesion. Staphylococci in milk secretion for 90 days. HH Trios, 85X.

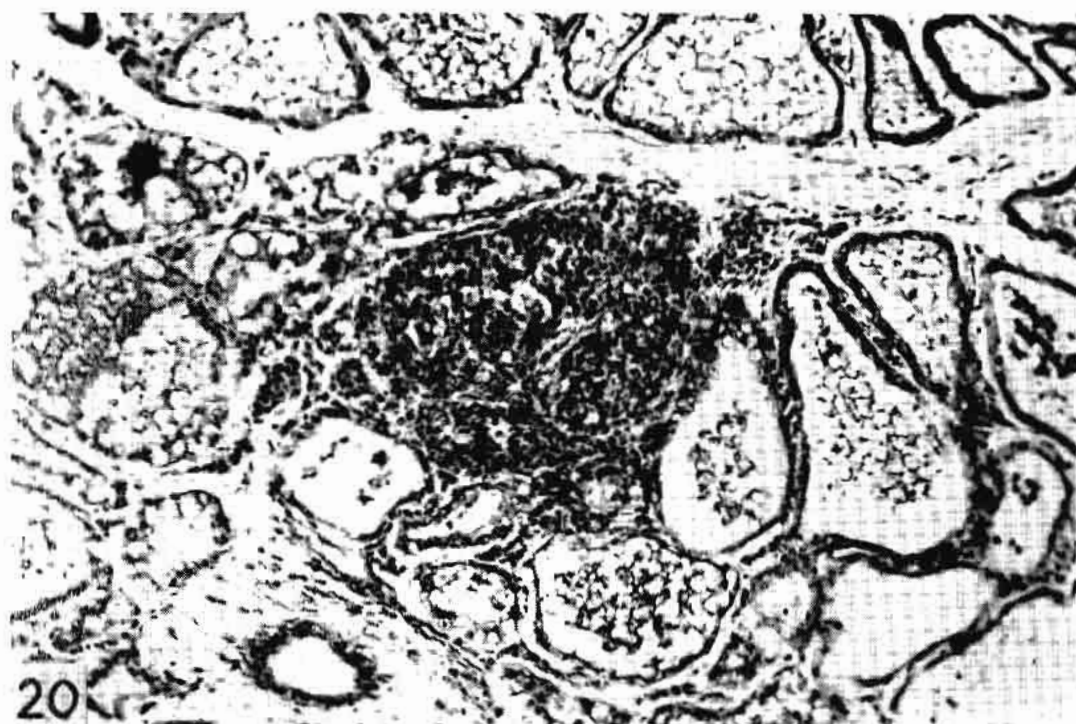

Fig. 20. Udder section from a four-year-old cow, 444 days continuous lactation, showing a mass of heterophils in several alveoli, an early lesion. Staphylococci in milk secretion for one year. Mall. Coll., 180X.

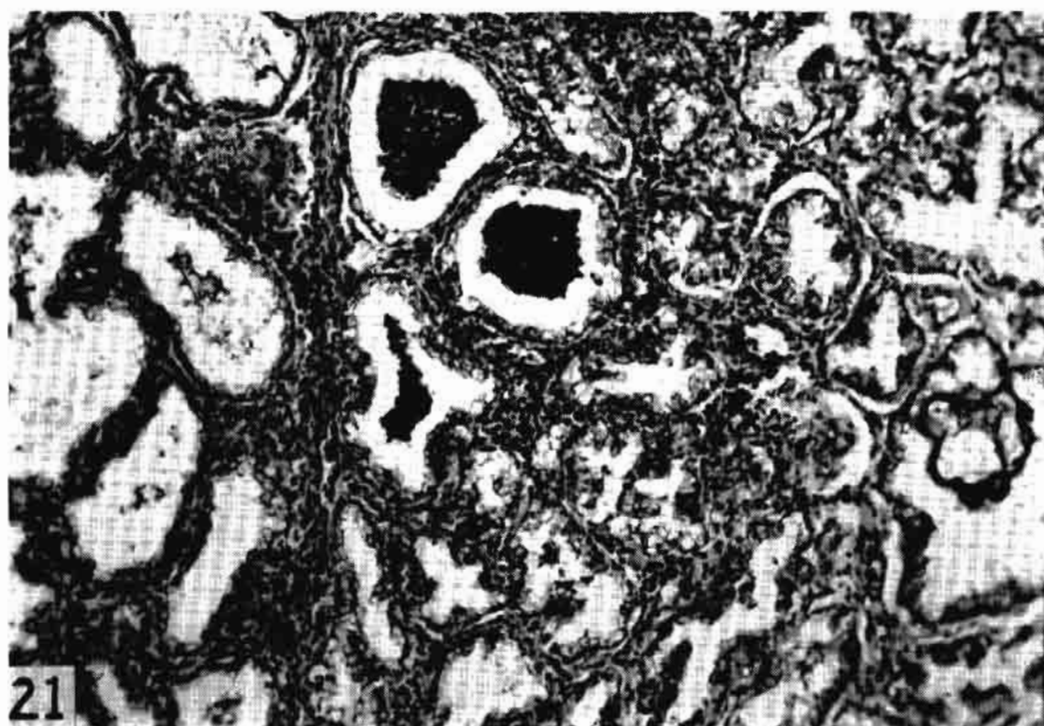


Fig. 21. Udder section from a three-year-old heifer, 23 days lactation, showing masses of heterophils in the alveoli, few heterophils and lymphocytes in the interalveolar tissue, slightly more advanced than Fig. 21. Staphylococci in milk secretion for 210 days before recent freshening. H & E, 120X.

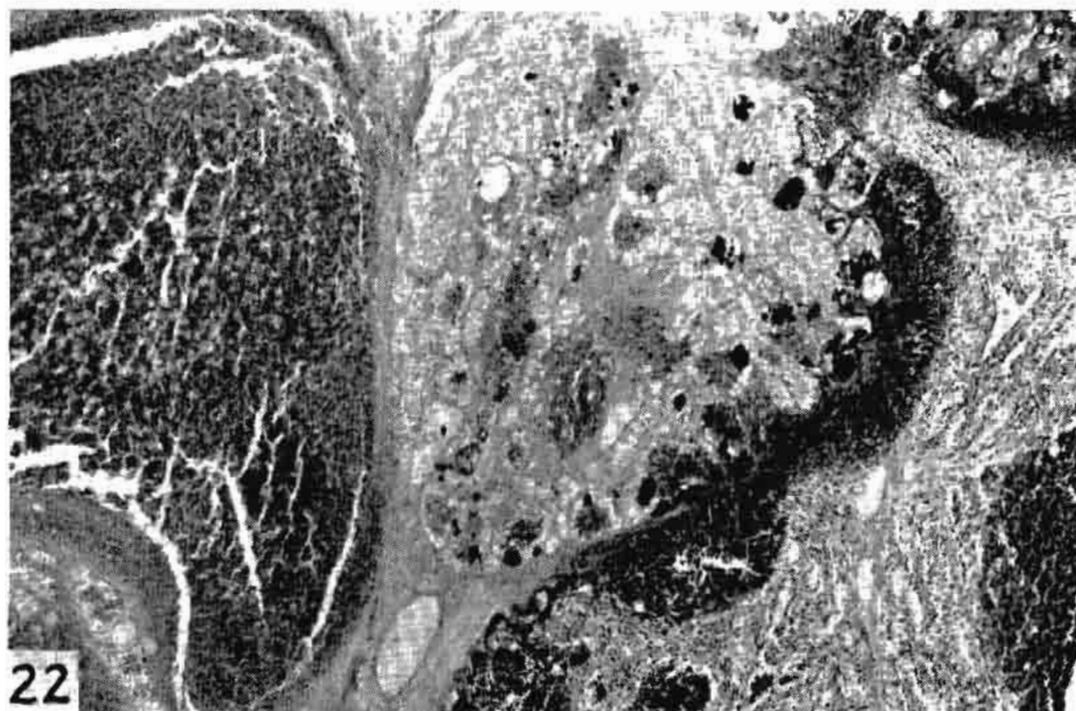


Fig. 22. Udder section from a six-year-old cow, 50 days lactation, showing at left duct engorged with heterophils, cocci, and cellular debris; at right a group of bacterial colonies, heterophils, and debris advancing on the center. Staphylococci in milk secretion for six days. BHEY, 45X.



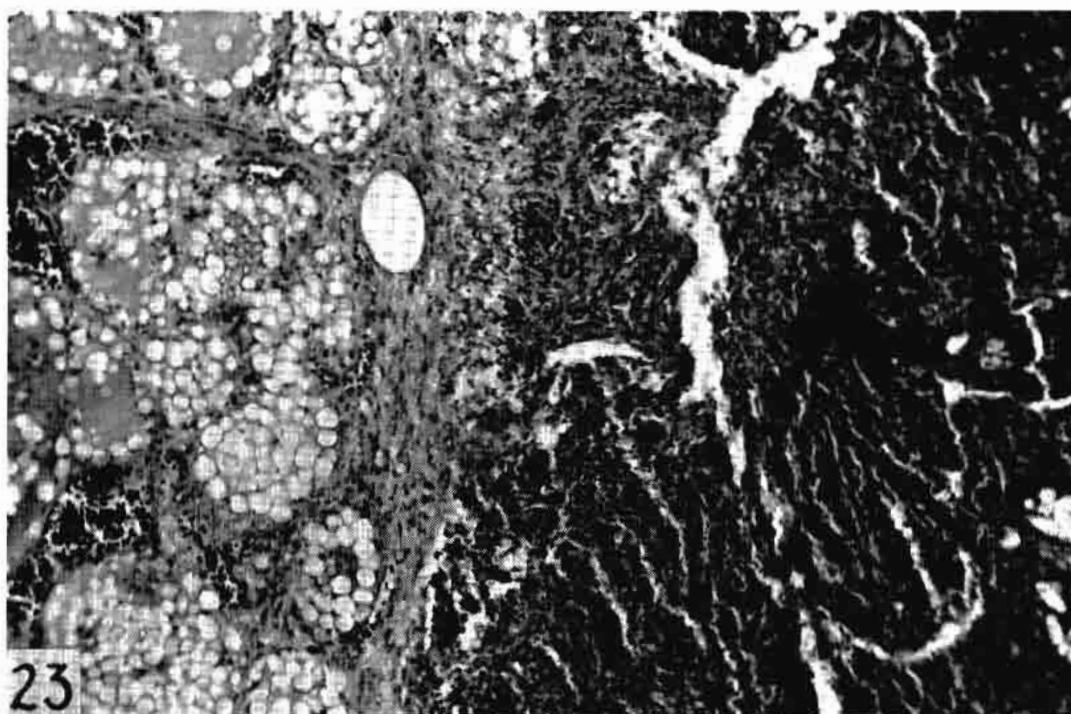


Fig. 23. Udder section from an eight-year-old cow, 540 days continuous lactation, showing leukocytes and cocci (dark stellate focus) at the right limited by the interlobular connective tissue. At the left a lobulus in a later phase of mastitis. Staphylococci in the milk secretion of unknown duration. BHEY, 180X.

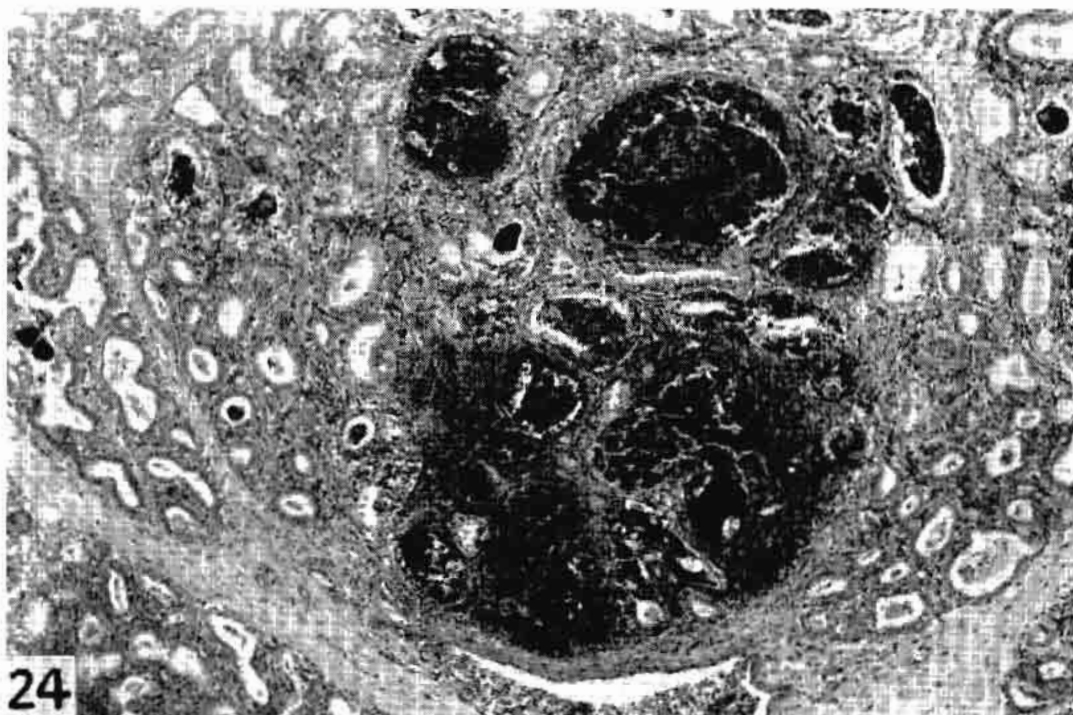


Fig. 24. Udder section from a 13-year-old cow, 24 days lactation, showing granulomas of cocci, lymphocytes, and fibroblasts; this corresponds to botryomycosis of some authors. Staphylococci in milk secretion at time of parturition. BHEY, 45X.

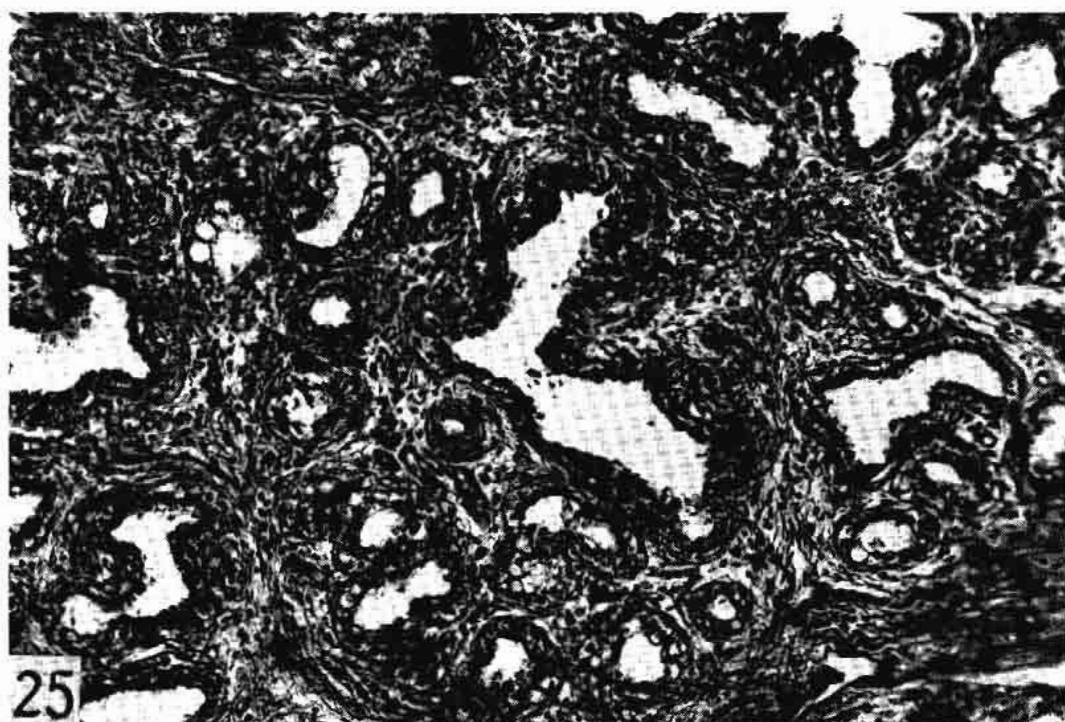


Fig. 25. Udder section from a six-year-old cow, 120 days lactation, showing almost complete involution. A few lymphocytes are present in the increased periductal tissue. Staphylococci in milk secretion for 90 days. H & E, 180X.

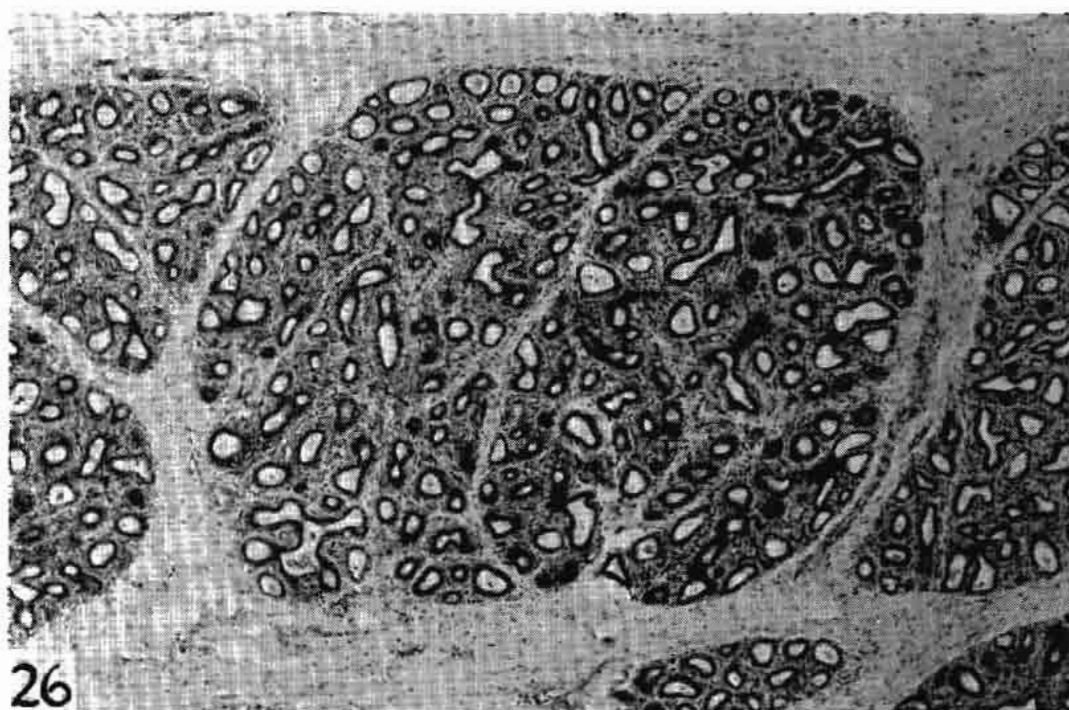


Fig. 26. Udder section from a six-year-old cow, 228 days lactation, showing lobuli completely involuted although some neighboring were functional. Note no evidence of any inflammatory reaction. Staphylococci in milk secretion for 210 days. H & E, 45X.



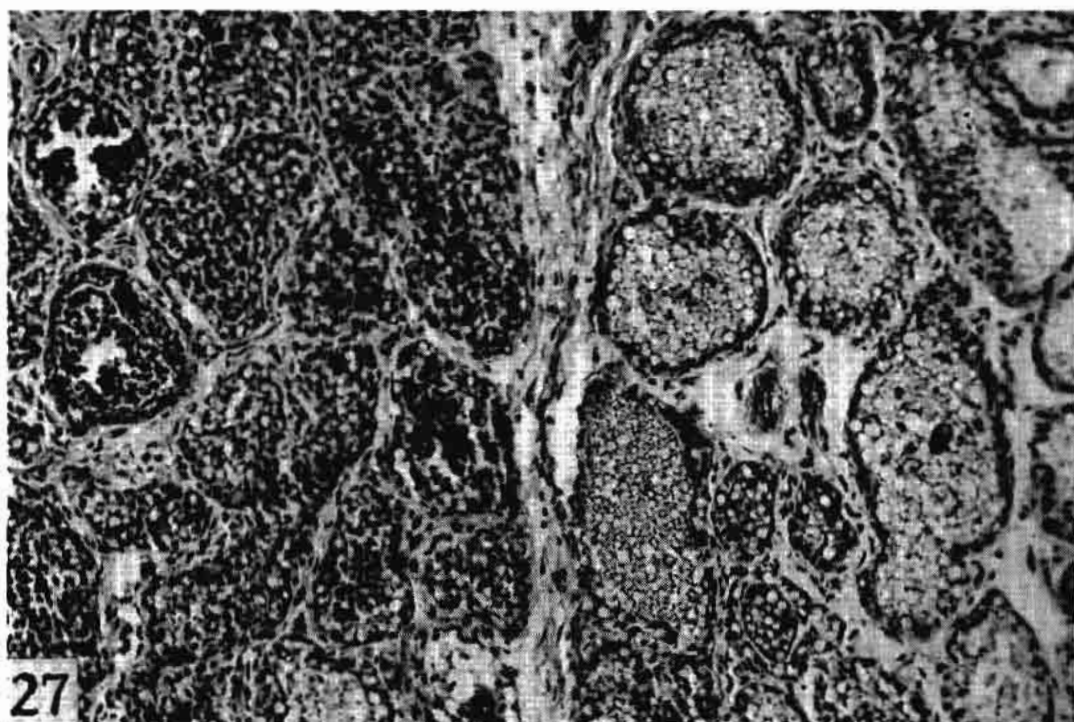


Fig. 27. Udder section from a three-year-old heifer, three days lactation, showing interalveolar edema to the right; to the left alveoli are filled with mononuclear cells. *A. aerogenes* in milk secretion for three days. BHEY, 180X.

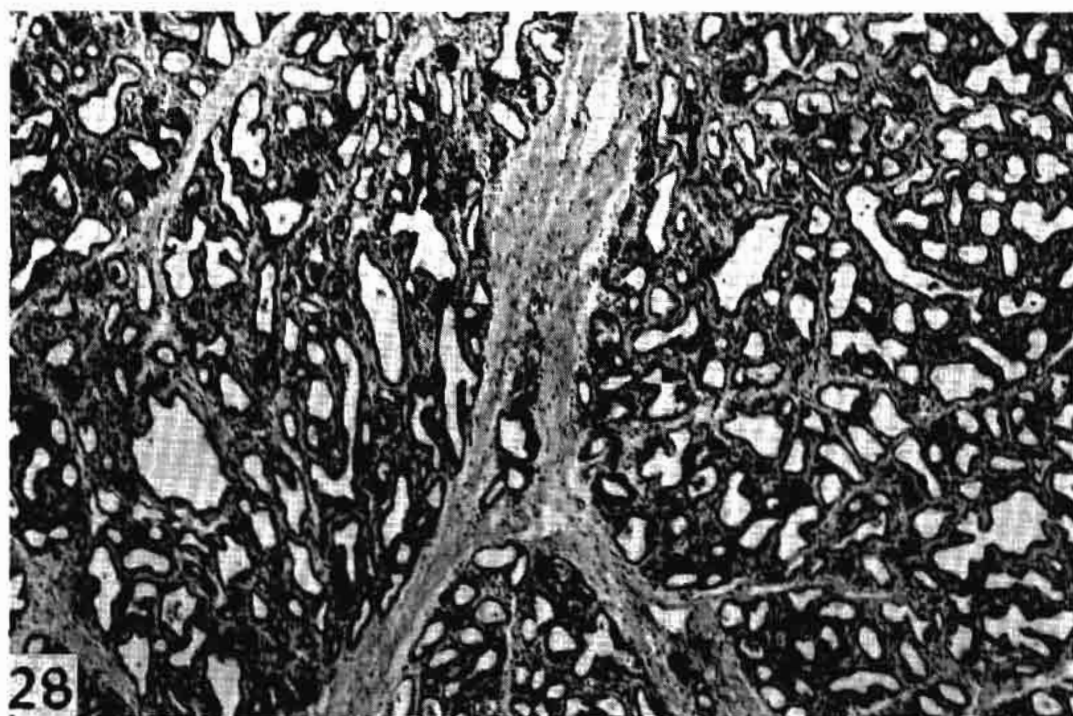


Fig. 28. Udder section from a three-year-old heifer, 60 days lactation, showing complete involution and lack of inflammatory reaction. *E. coli* in milk secretion for 60 days. BHEY, 45X.

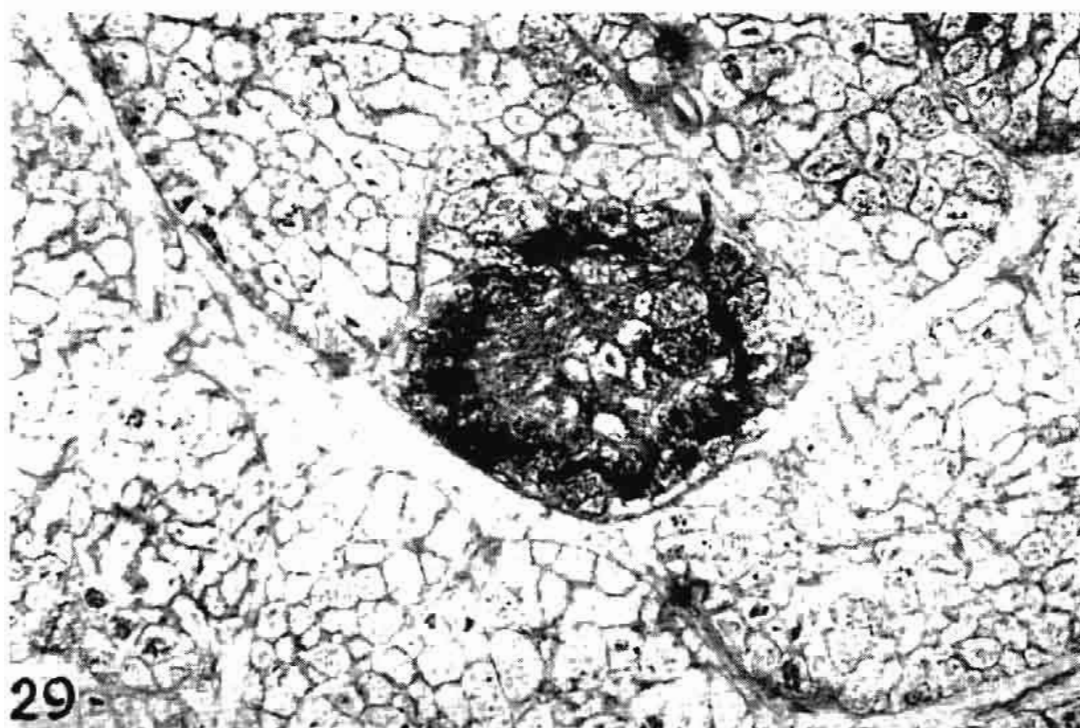


Fig. 29. Udder section from a six-year-old cow, five days lactation, showing a necrotic focus with a rim of mononuclear cells. *A. aerogenes* in milk secretion for four days. HH Trios, 45X.

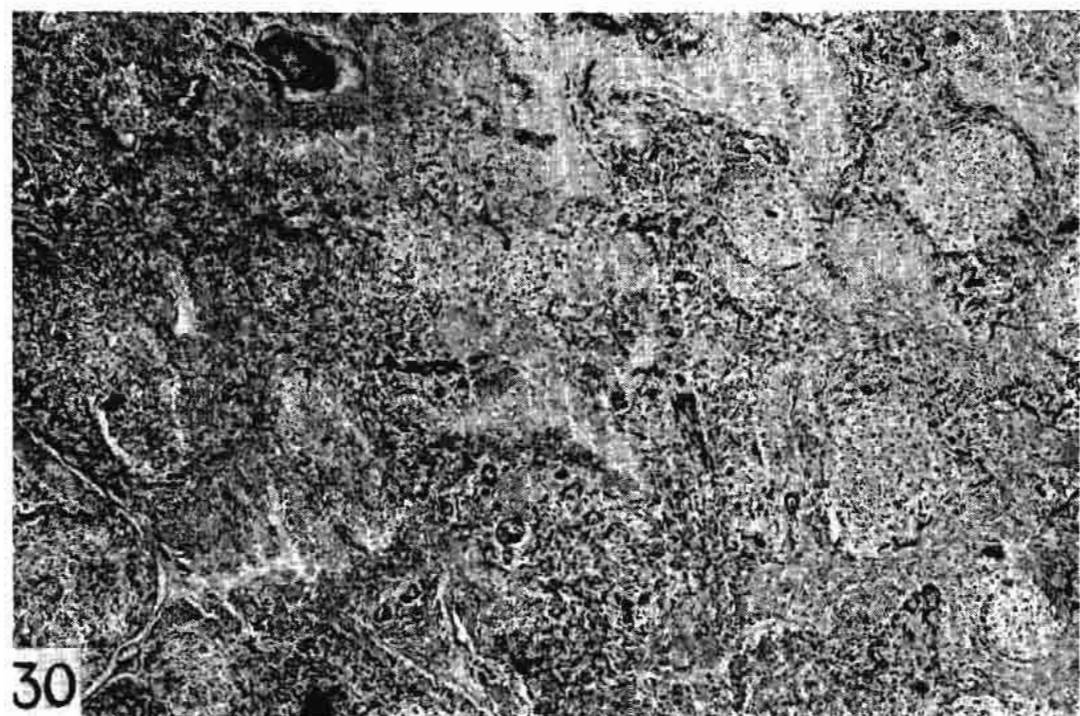


Fig. 30. Udder section from a six-year-old cow, five days lactation, showing entire area in a necrotic state. *A. aerogenes* in milk secretion for four days. HH Trios, 120X.



Fig. 31. Udder section from a six-year-old cow, 252 days lactation, showing large necrotic area infiltrated by mononuclear cells at top. Granulation tissue is filling in the necrotic area from below. *E. coli* in milk secretion for 60 days. H & E, 45X.

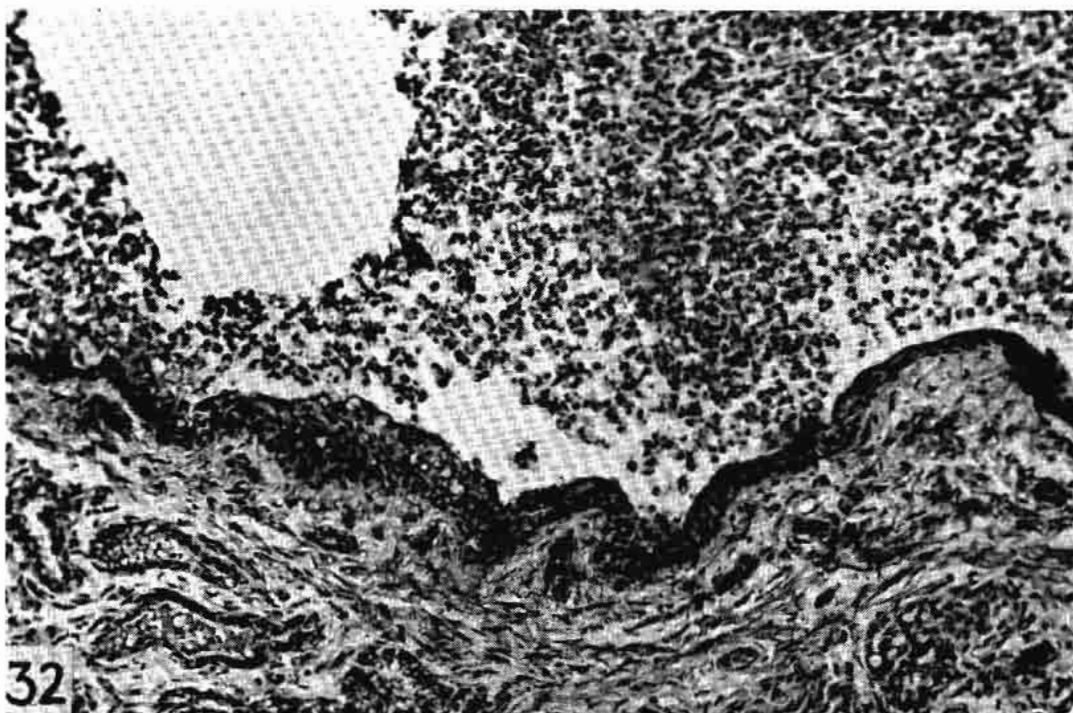


Fig. 32. Cisternal area from a three-year-old heifer, three days lactation, showing hyperplasia of the epithelium and masses of heterophils in the lumen, not always seen in coliform mastitis. *A. aerogenes* in milk secretion for three days. BHEY, 180X.



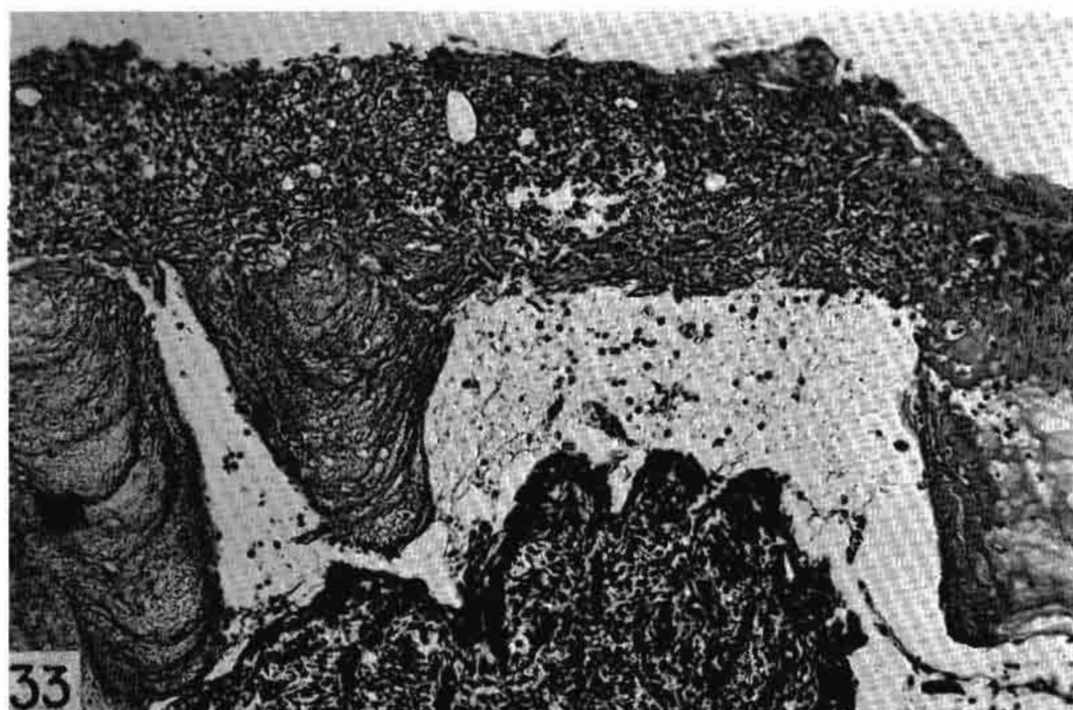


Fig. 33. Cisternal area from a six-year-old cow, five days lactation, showing a fibrinous clot containing mononuclears, which also infiltrate the lamina propria. *A. aerogenes* in milk secretion for four days. HH Trios, 180X.

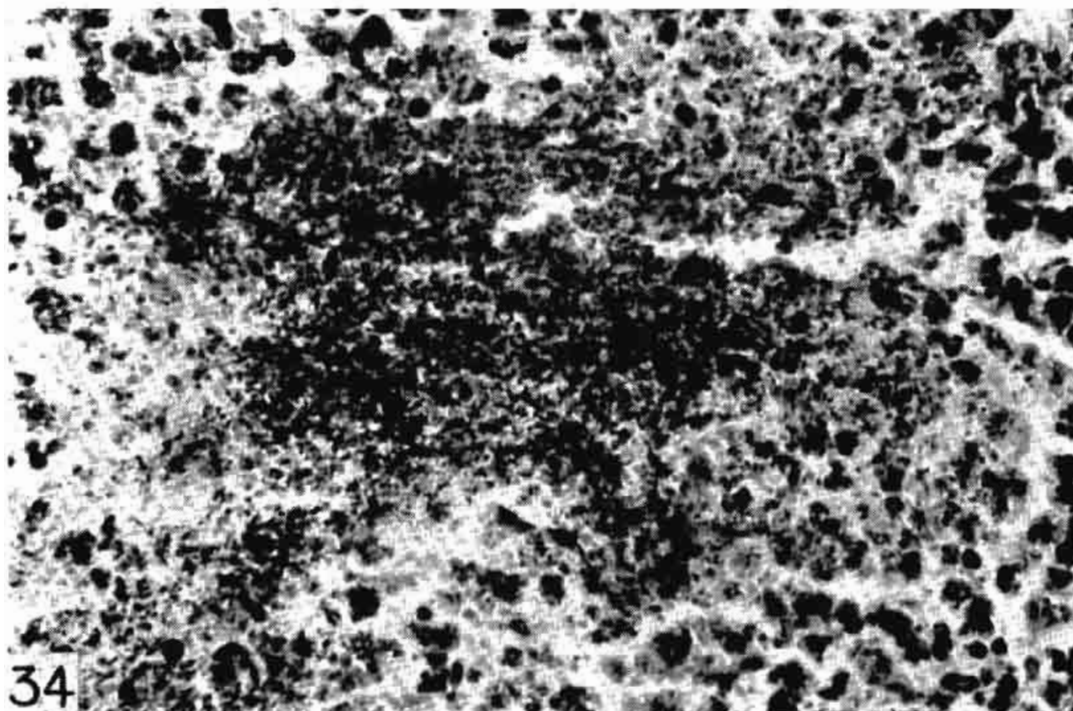


Fig. 34. Udder section from a seven-year-old cow, three days lactation, showing an alveolus containing many bacteria in an edematous area containing leukocytes. *C. pyogenes* in milk secretion for three days. HH Trios, 650X.

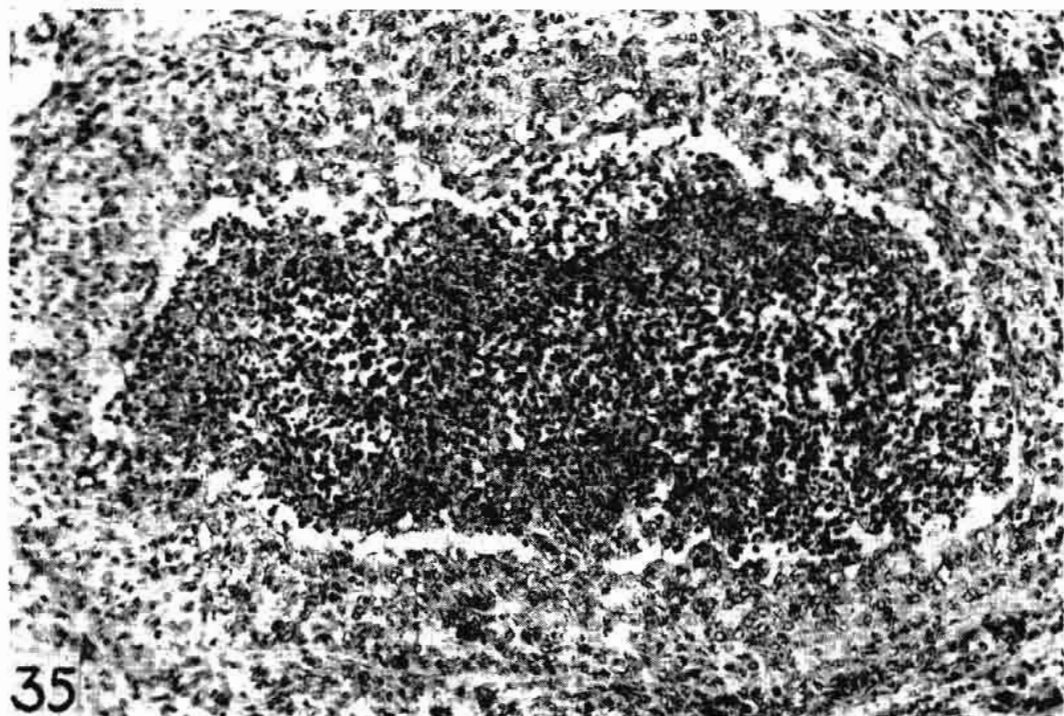


Fig. 35. Another udder section of same cow in Fig. 34, showing an interlobular duct filled with bacteria and heterophils; the mucosa is edematous and hyperplastic. *C. pyogenes* in milk secretion for three days. HH Trios, 180X.

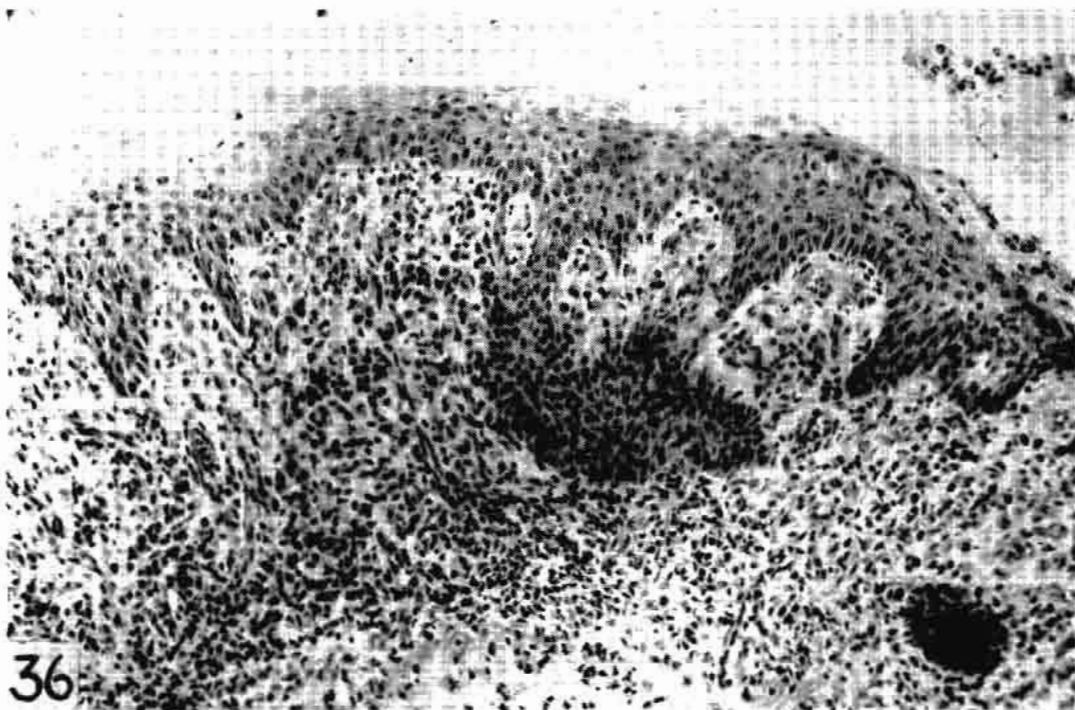

Fig. 36. Cisternal area of same cow as in Fig. 34. There is complete squamous metaplasia of the cisternal epithelium. Note the resemblance to a basal cell carcinoma. *C. pyogenes* in milk secretion for three days. HH Trios, 180X.



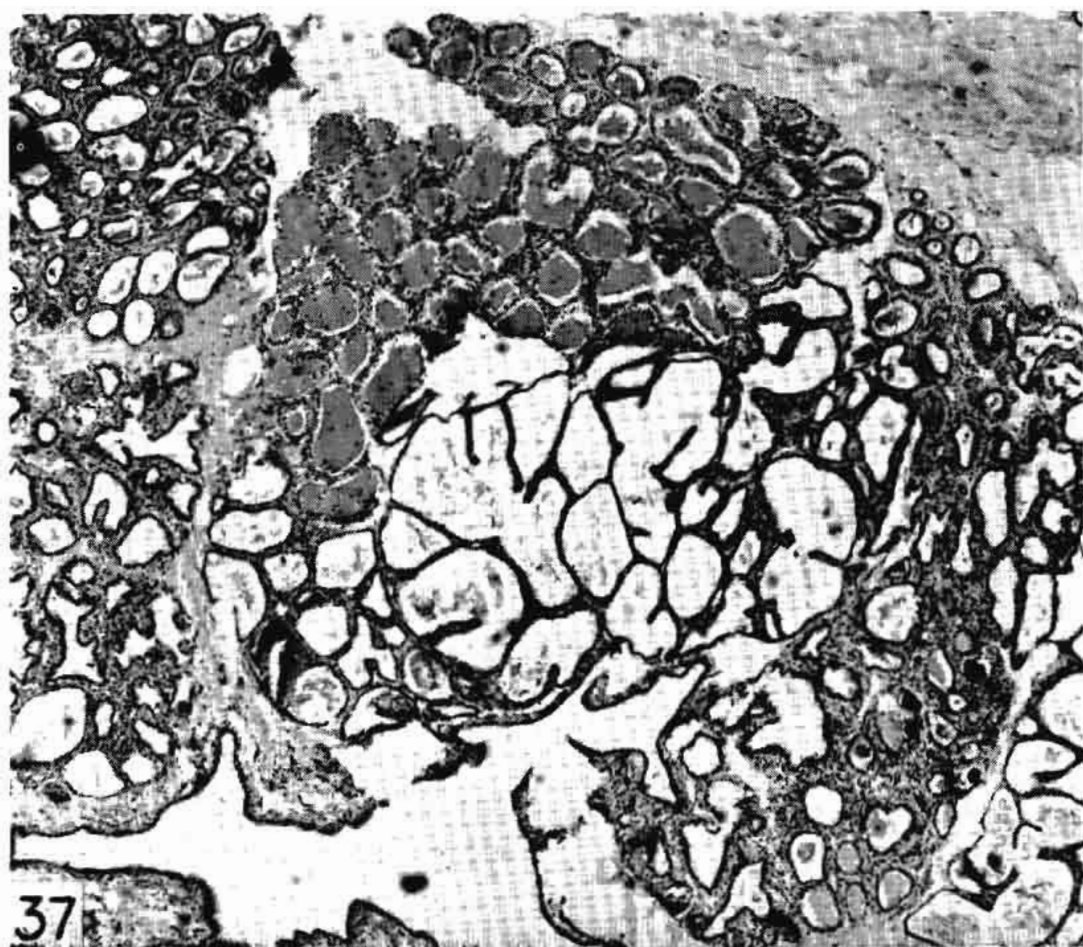


Fig. 37. Udder section from a ten-year-old cow, 330 days continuous lactation, showing an entire lobulus. The upper left segment contains heterophils and clotted milk of an early lesion, the central alveoli are markedly dilated, the lower right contains corpora amylacea from an old lesion. *Str. dysgalactiae* in milk secretion for 60 days. BHEY, 45X.

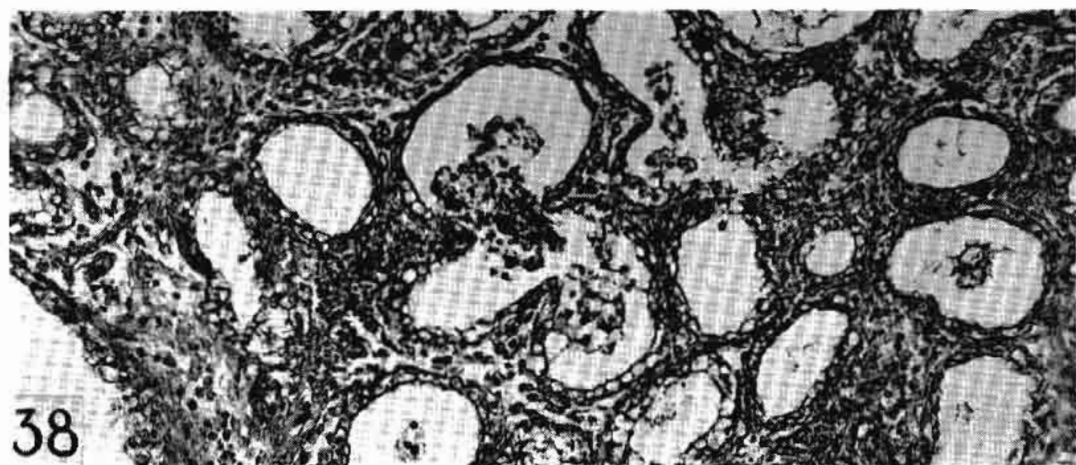


Fig. 38. Udder section from a six-year-old cow, 120 days lactation, showing a few heterophils in alveoli and exudate spreading into other lumina. A very early lesion. *Str. agalactiae* in milk secretion for 60 days. HH Trios, 60X.

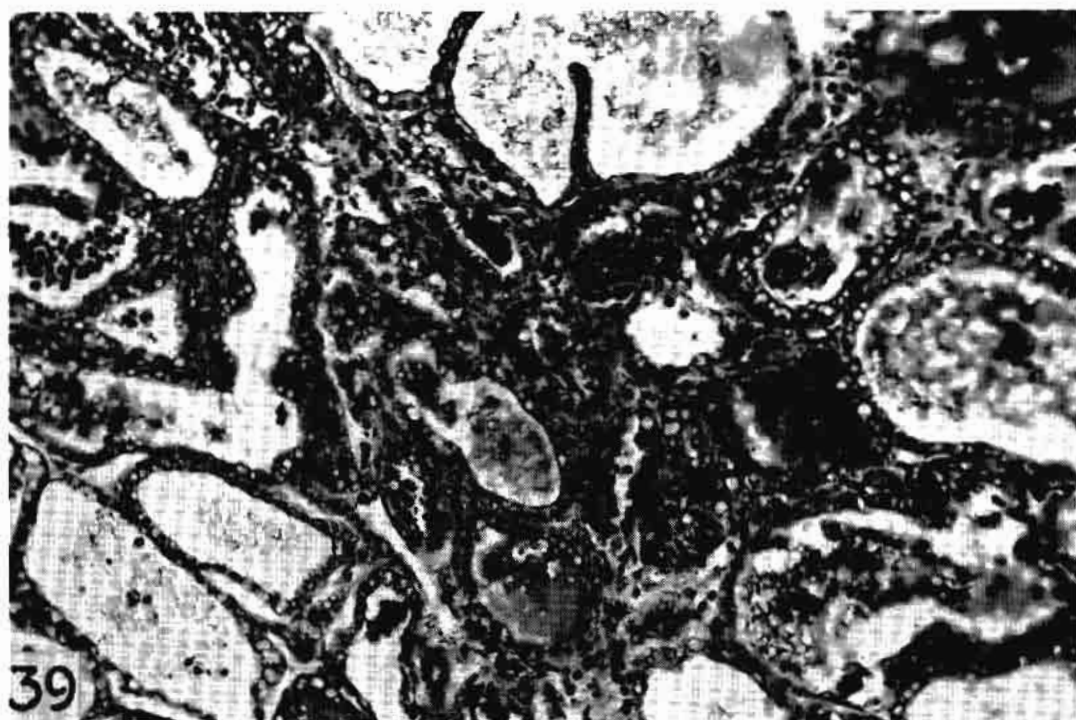


Fig. 39. Udder section from an aged cow of unknown length of lactation, showing heterophils in alveoli and in interalveolar tissue. More advanced than lesion in Fig. 38. *Str. agalactiae* in milk secretion for unknown length of time. HH Trios, 180X.

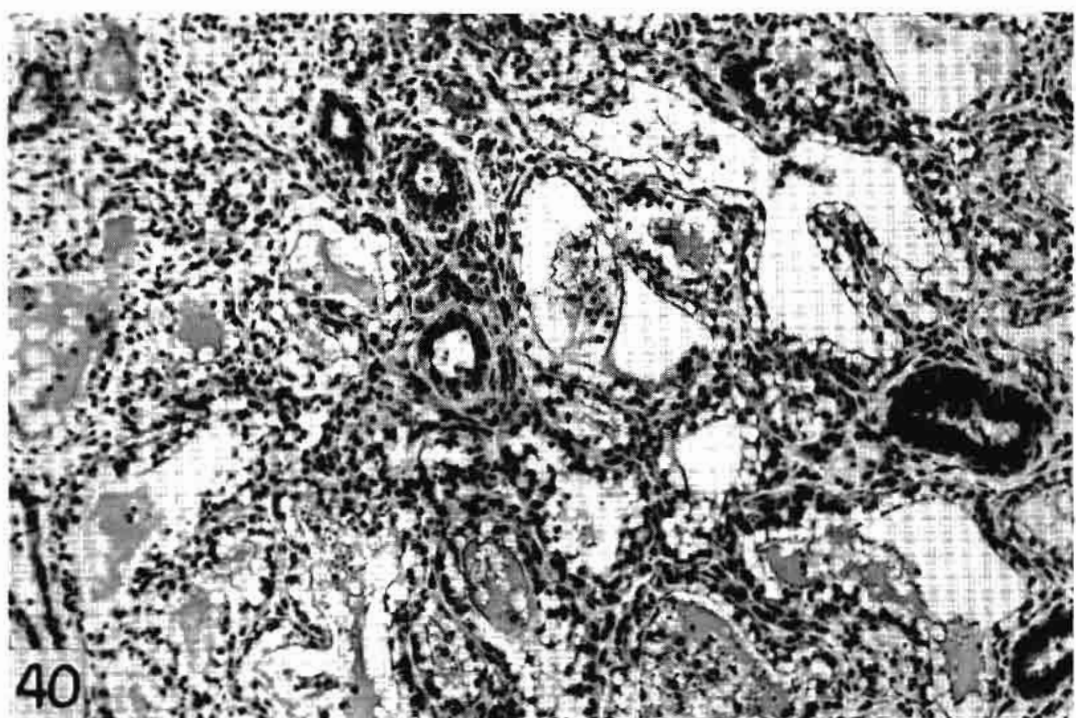


Fig. 40. Udder section from an 18-year-old cow, of 859 days continuous lactation, showing some evidence of function. The epithelium is vacuolated and lymphocytes are present in the periductal tissue. *Str. agalactiae* in milk secretion for six years. H & E, 180X.

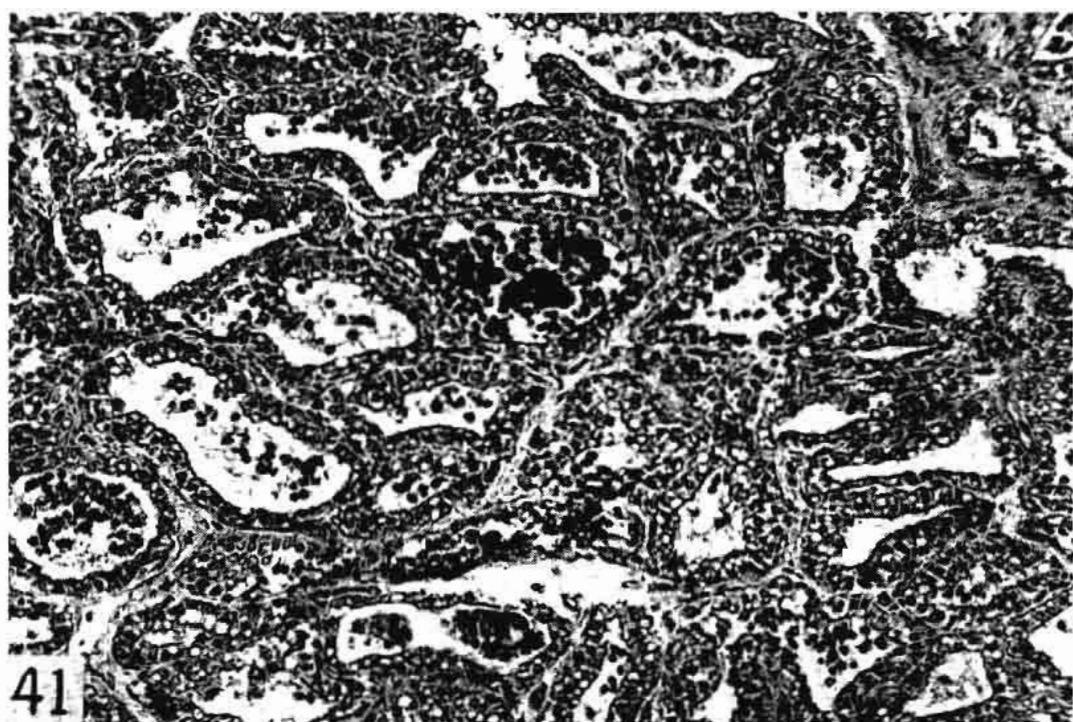


Fig. 41. Udder section from same cow as in Fig. 39, showing masses of heterophils in lumina and atrophying alveoli. The lesion is more advanced than Fig. 39. *Str. agalactiae* in milk secretion for unknown length of time. HH Trios, 180X.

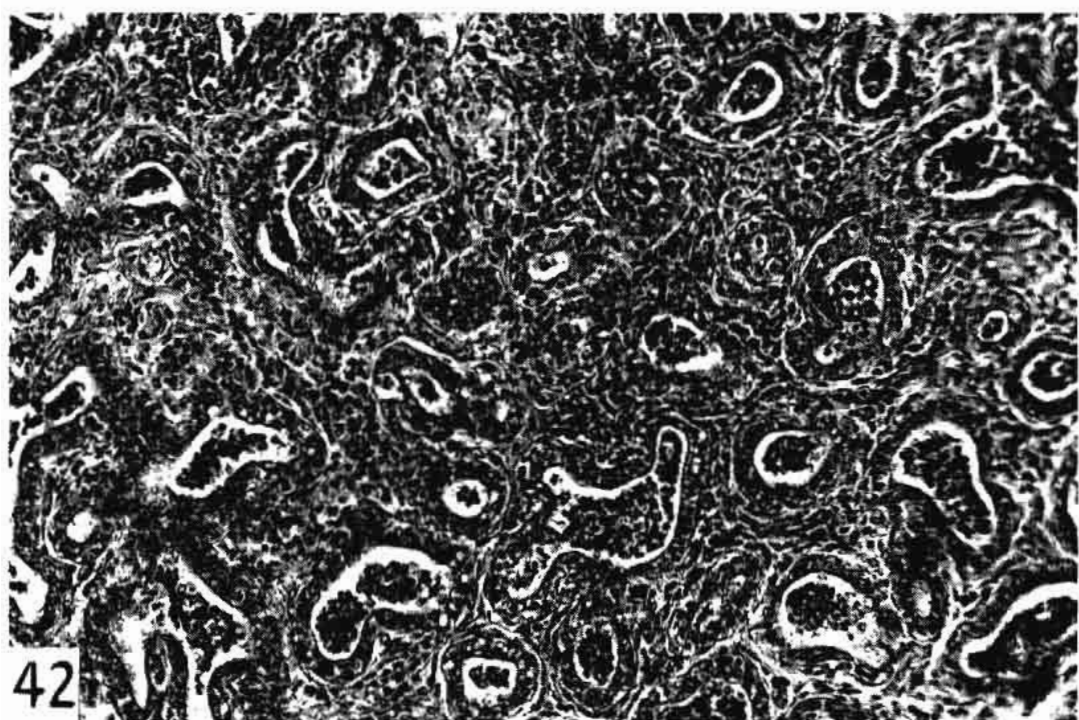
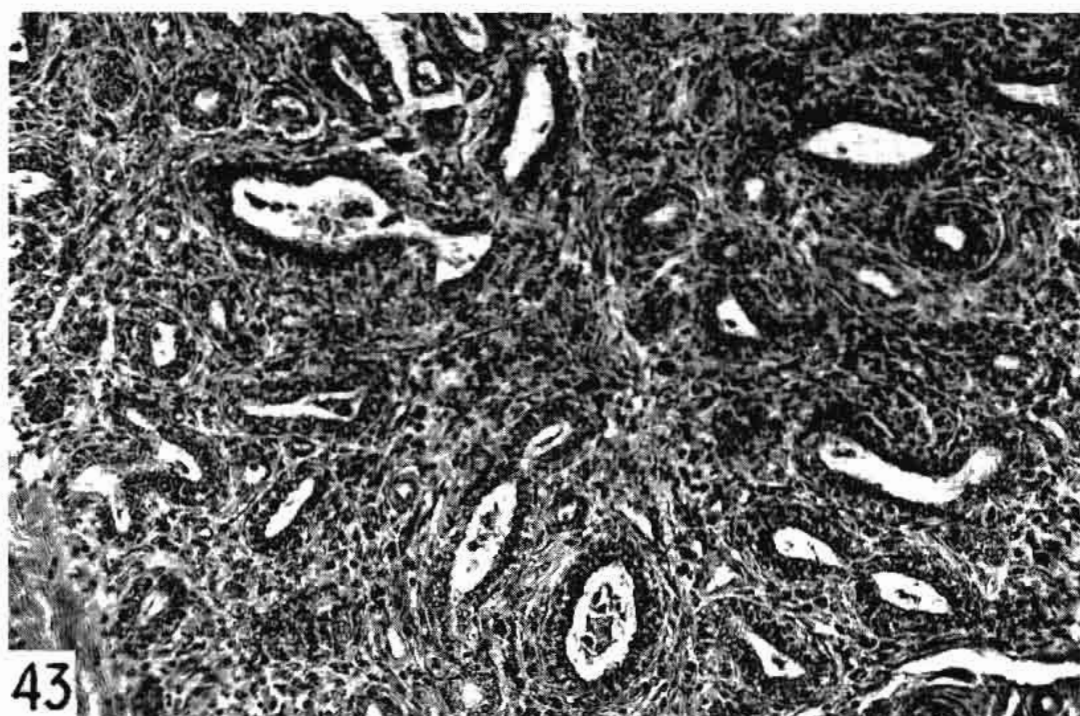


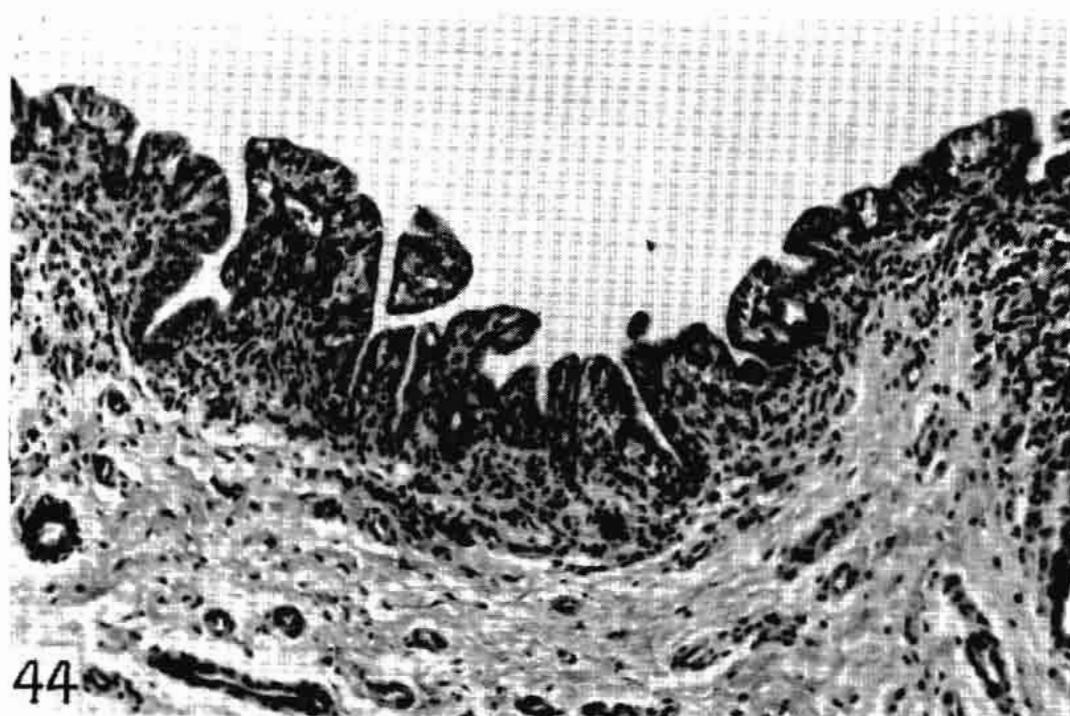
Fig. 42. Udder section from an aged cow of unknown length of lactation, showing heterophils in atrophied alveoli and in the increasing periductal tissue. More advanced than Fig. 41. *Str. agalactiae* in the milk secretion for an unknown length of time. HH Trios, 180X.





43

Fig. 43. Udder section from a six-year-old cow, 40 days lactation, showing almost complete involution. The highly cellular periductal tissue contains a few leukocytes. Note relative lack of inflammatory reaction. *Str. uberis* in milk secretion for 120 days. HH Trios, 180X.



44

Fig. 44. Cisternal area of a four-year-old cow, 362 days continuous lactation, showing lymphocytic infiltration of the lamina propria and slight hypertrophy of the epithelium. *Str. uberis* in milk secretion for 90 days. H & E, 180X.



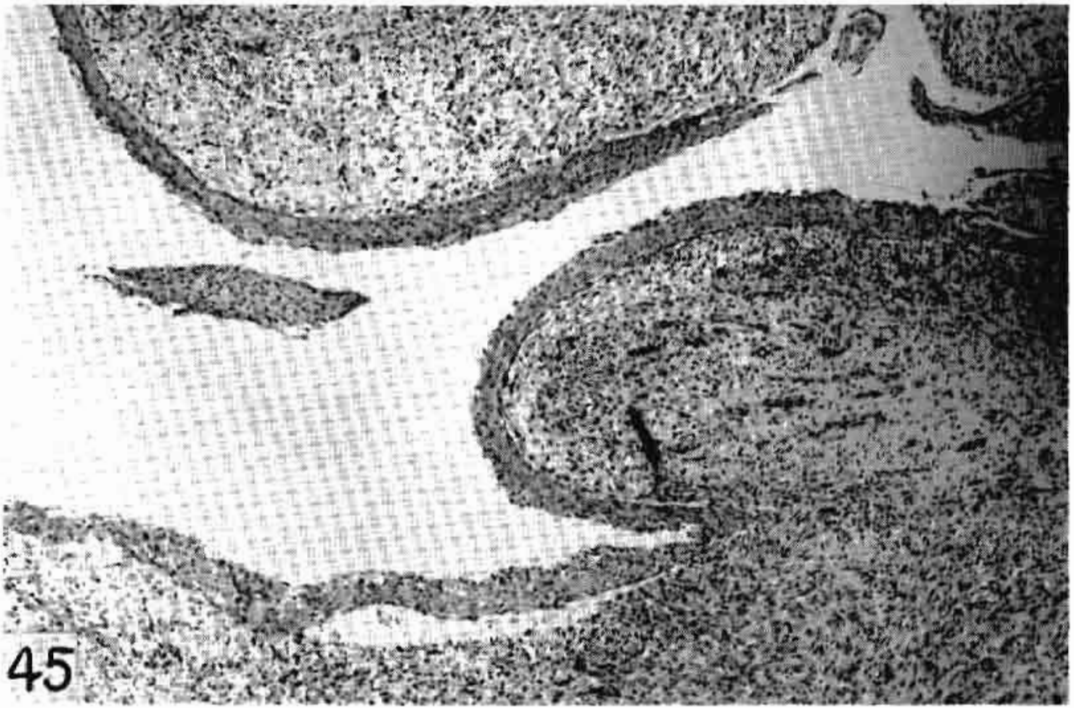


Fig. 45. Cisternal area from an 11-year-old cow, 185 days lactation, showing squamous metaplasia and granulation tissue in place of lamina propria. Secretion negative at the time of death, but two years previously *Str. uberis* and later *Str. agalactiae*, which disappeared spontaneously. H & E, 45X.

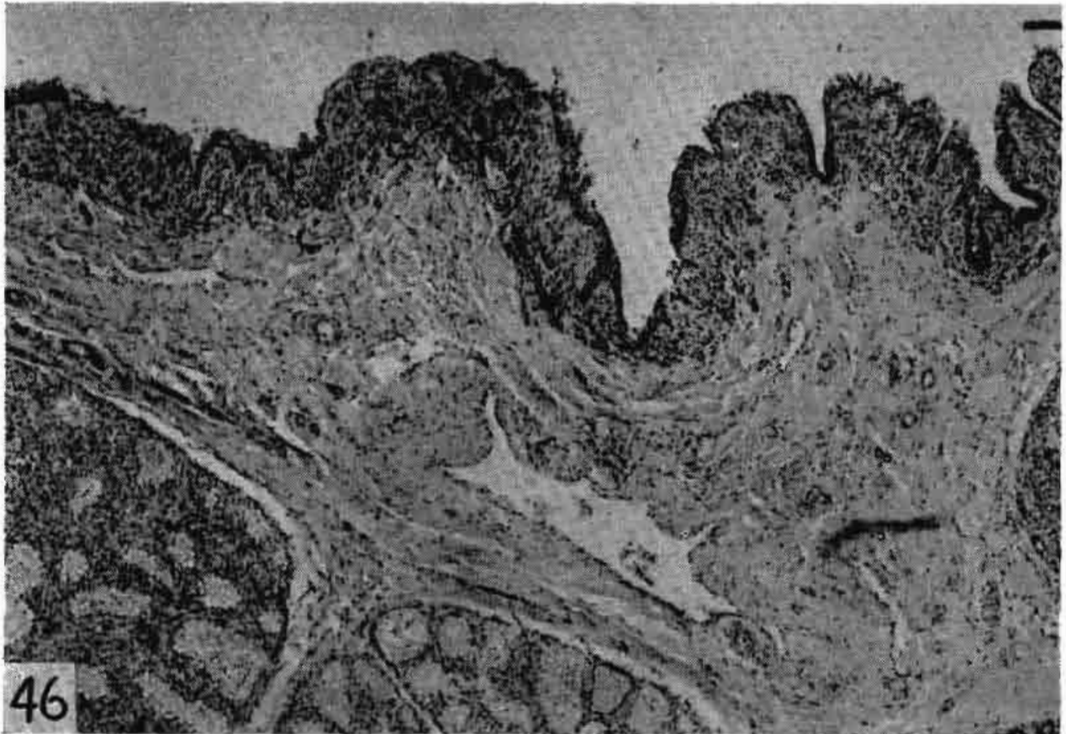


Fig. 46. Cisternal area from a six-year-old cow, 20 days lactation, showing sharply limited infiltration of the lamina propria and narrowing of the indentations. *Str. uberis* in milk secretion for 180 days. HH Trios, 45X.

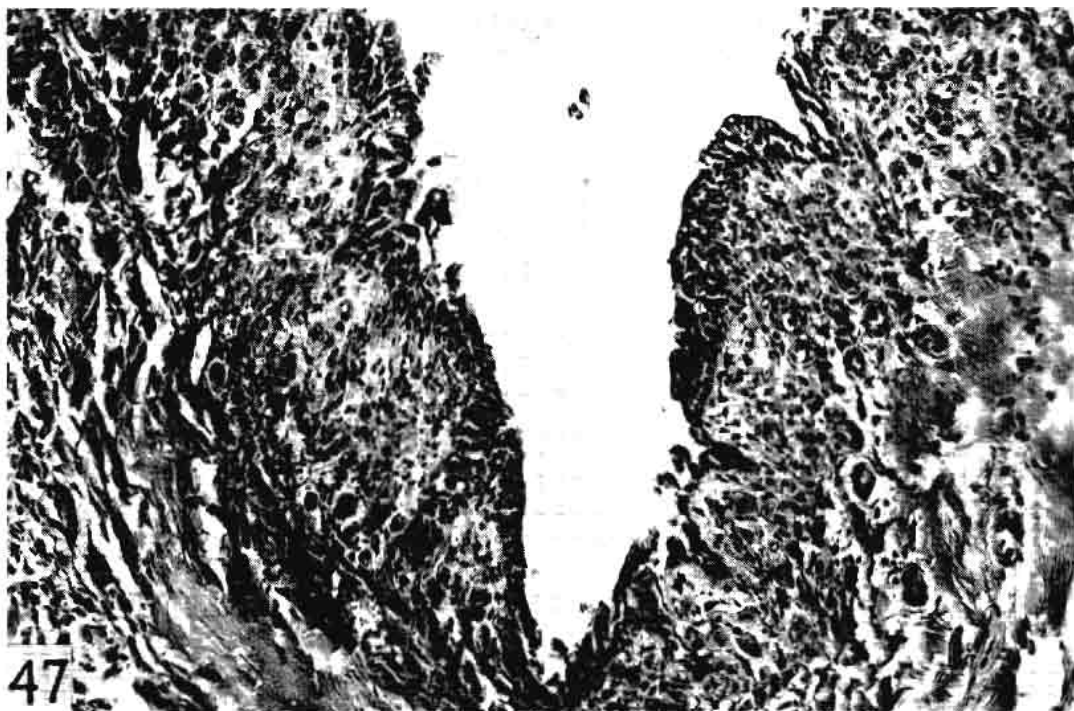


Fig. 47. Same as in Fig. 46, showing epithelial hyperplasia alternating with desquamation of the epithelium and lymphocytic infiltration with edema in the lamina propria. HH Trios, 180X.



Fig. 48. Cisternal area from an 18-year-old cow, 859 days lactation, showing epithelial hyperplasia, lymphocytic infiltration and edema of the lamina propria to cause marked narrowing of the indentations. *Str. agalactiae* in milk secretion for five years. H & E, 180X.

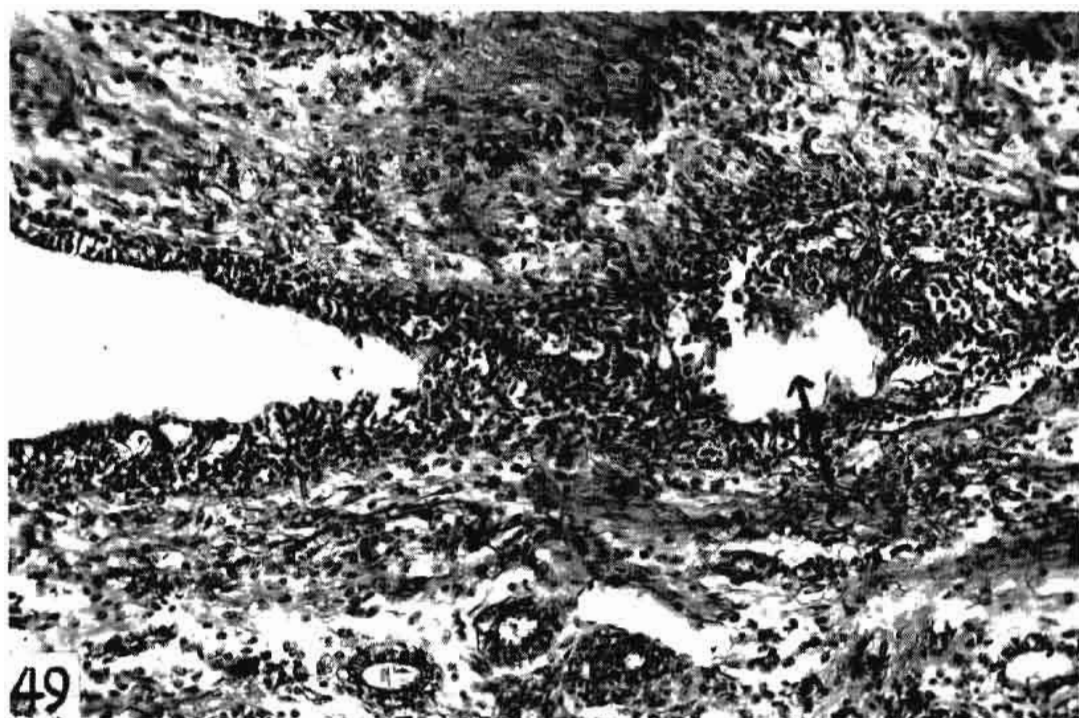


Fig. 49. Cisternal area from an aged cow of unknown history showing adhesion of hyperplastic epithelium forming a pocket (arrow). *Str. agalactiae* in milk secretion for unknown length of time. HH Trios, 180X.

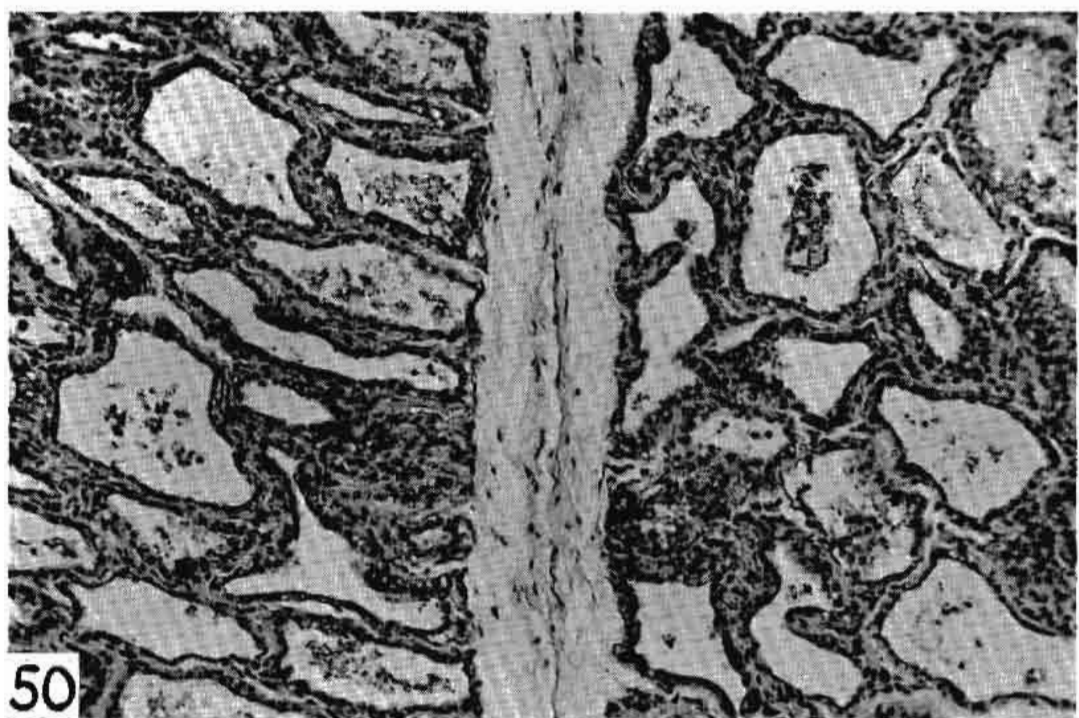


Fig. 50. Udder section from an eight-year-old cow, 45 days lactation, showing slight evidence of functional ability. Section was from lower third of the udder. *Str. agalactiae* in milk secretion for five years. H & E, 180X.



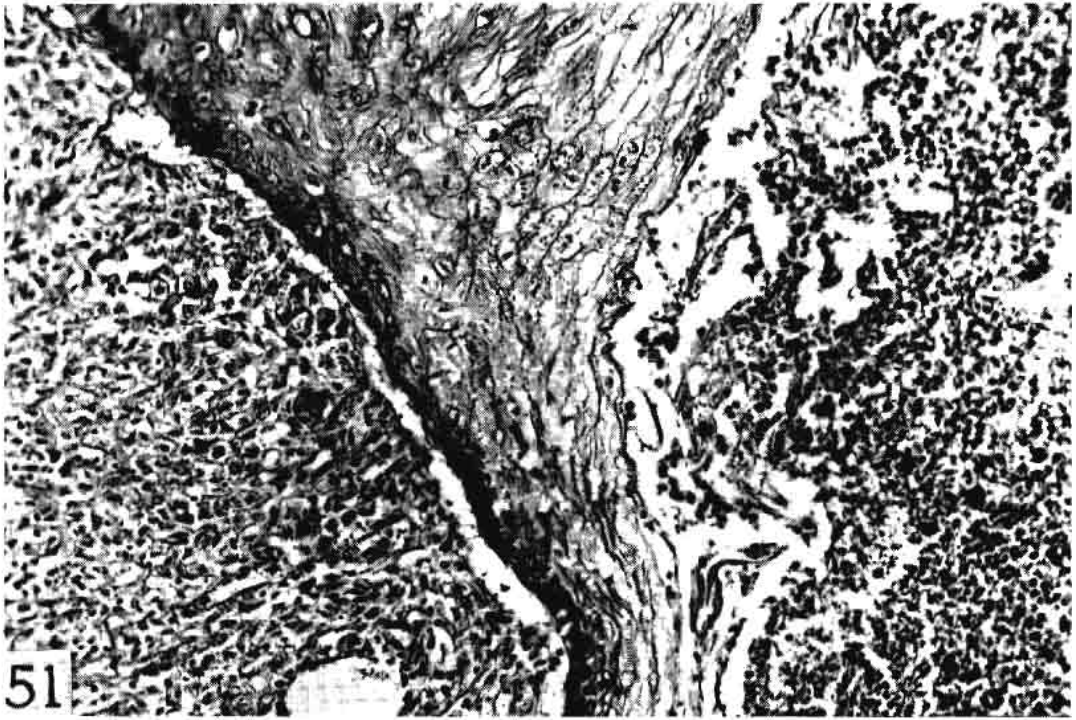


Fig. 51. Cisternal area from a four-year-old cow, 148 days lactation, showing granulation tissue at left which is within a large duct. In the center is the hyperplastic epithelium of the ductal wall, at right is a periductal abscess eroding the epithelium. A beta-hemolytic streptococcus in milk secretion, probably *Str. agalactiae*, for less than 30 days. H & E, 180X.

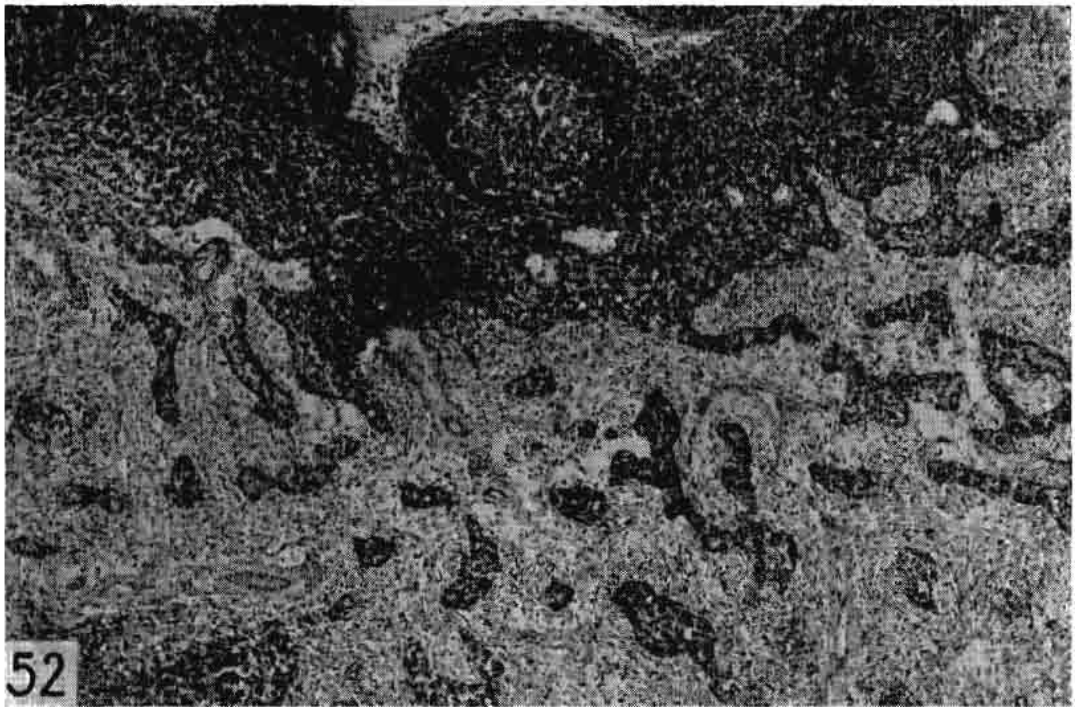


Fig. 52. Right supramammary lymph node from a four-year-old cow, 441 days continuous lactation. This node is considered normal although the sinusoidal walls of the (lower) medullary portions are quite prominent. Corresponding half of udder bacteriologically and histologically negative. H & E, 45X.



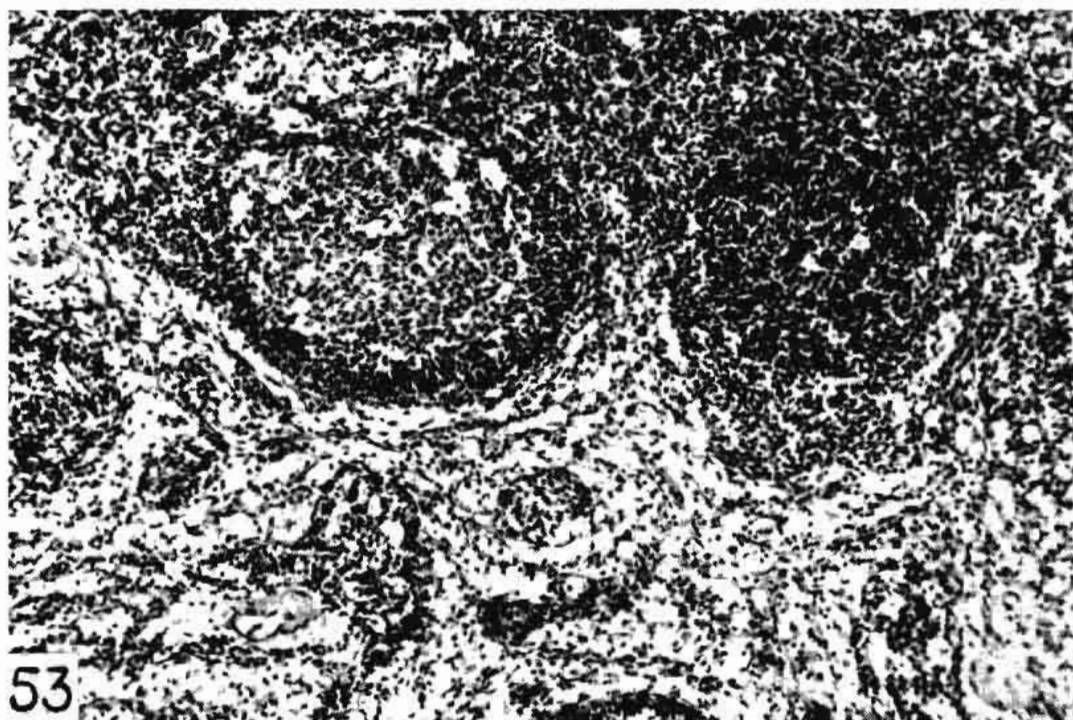


Fig. 53. Same cow as in Fig. 52. Left supramammary lymph node, showing narrowing of the medullary portion owing to cortical hyperplasia. *Str. uberis* in milk secretion of left side of udder for one year. H & E, 180X.




Fig. 54. Medulla of a supramammary lymph node from a five-year-old cow, 152 days lactation, showing sinuses engorged with heterophils and hyperplastic lymphocytic elements. Staphylococci in milk secretion for 540 days. H & E, 120X.




Fig. 55. Higher magnification of Fig. 54, showing heterophils and lymphocytic elements. H & E, 650X.

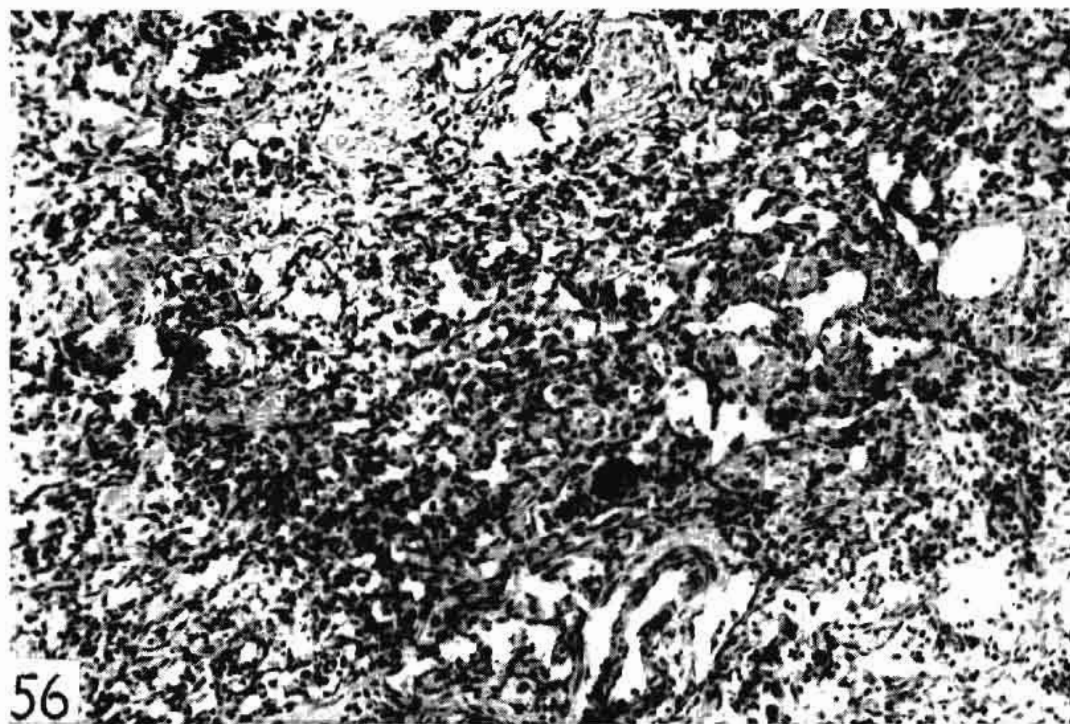


Fig. 56. Supramammary lymph node from a 13-year-old cow, 47 days lactation, showing medullary portion in early stages of fibrosis. *Str. agalactiae* in secretion for two years. H & E, 180X.

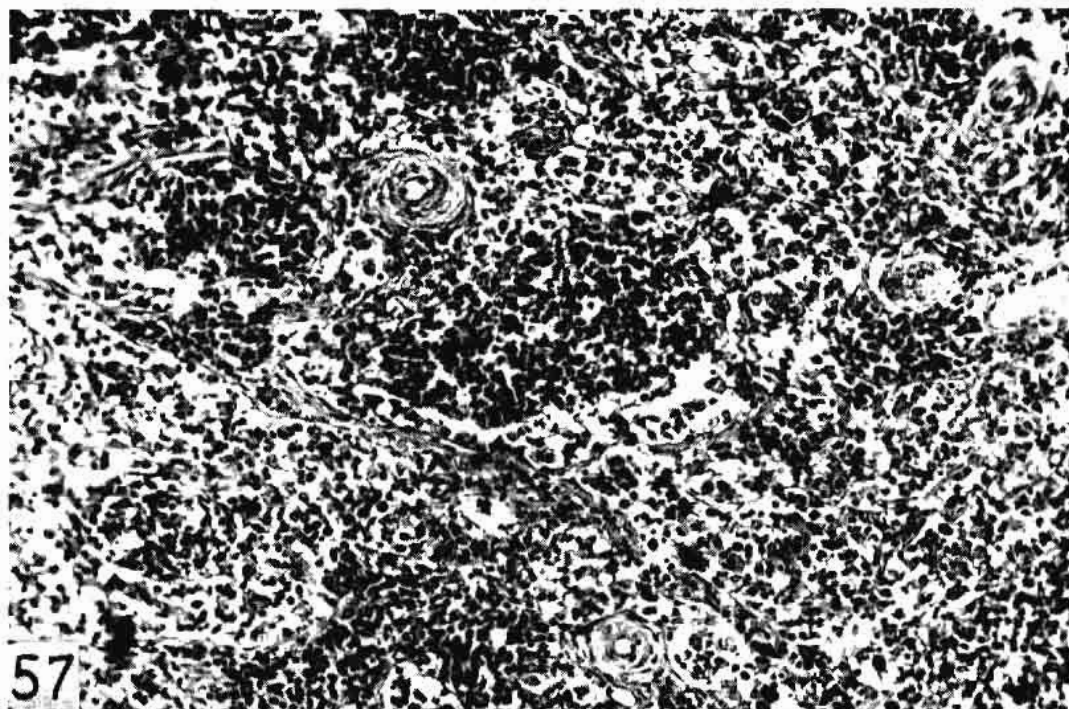


Fig. 57. Supramammary lymph node from a six-year-old cow, 252 days lactation, showing medullary portion with prominent sinusoidal walls and proliferated lymphocytes in the sinuses. Staphylococci and coliform bacteria in the milk secretion for 180 days. H & E, 180X.

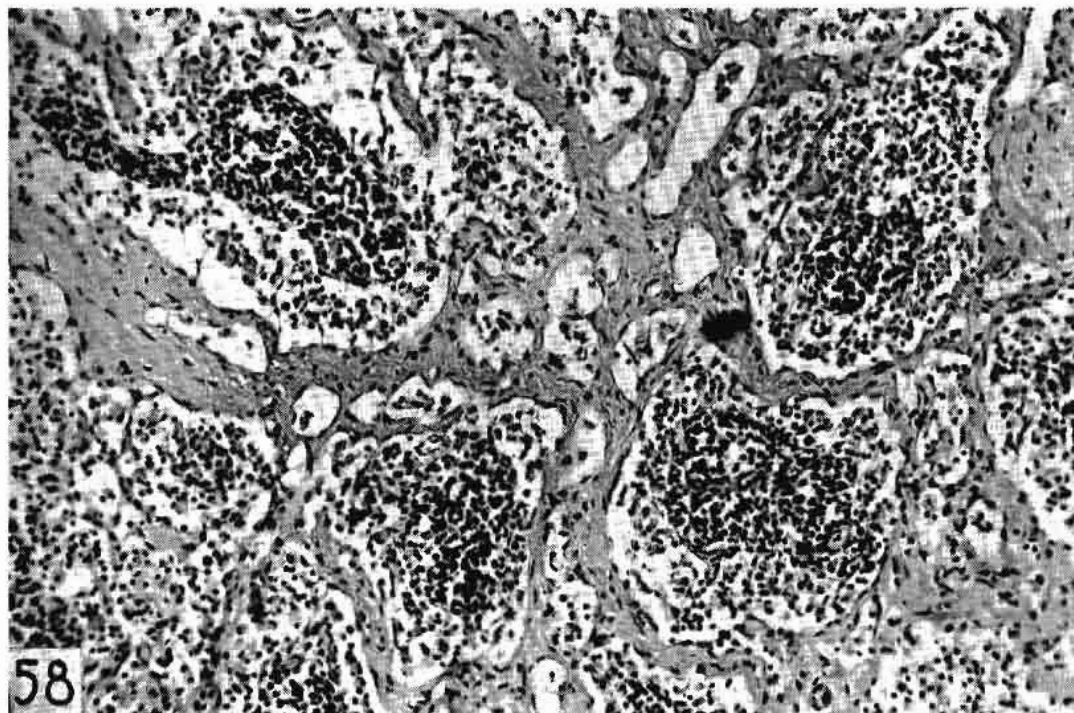


Fig. 58. Supramammary lymph node from a four-year-old cow, 23 days lactation, showing definite sclerosis of sinusoidal walls and lymphocytic proliferation in the sinuses. *Str. agalactiae* in milk secretion for one year. H & E, 180X.



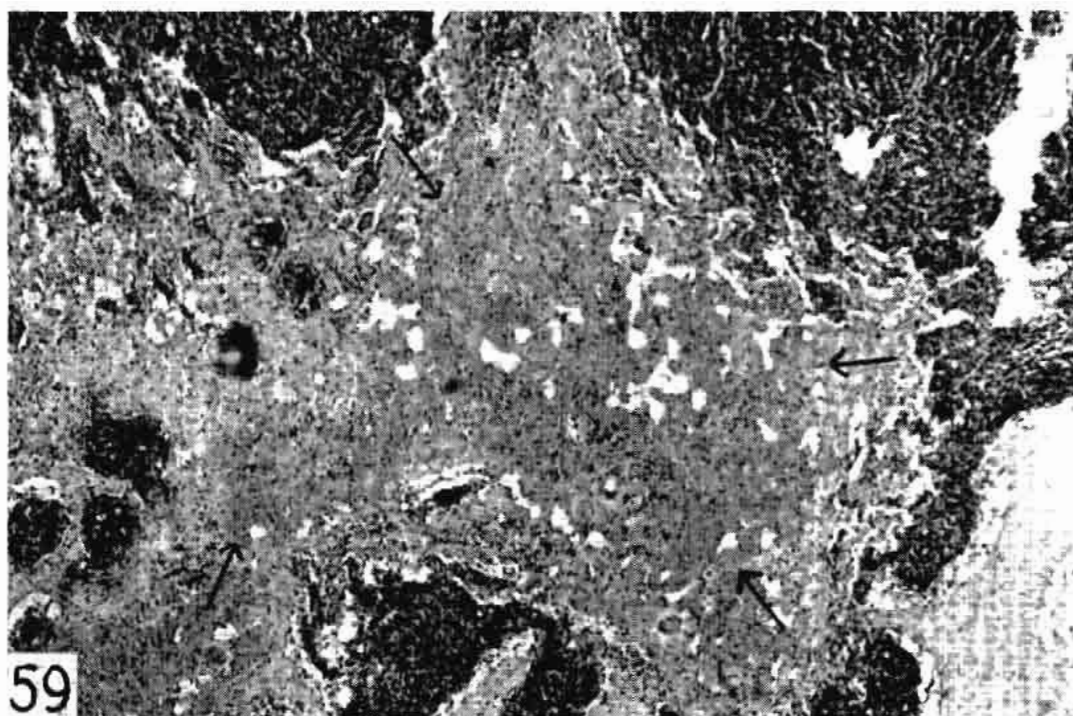


Fig. 59. Supramammary lymph node from an 18-year-old cow, 859 days lactation, showing a large hemorrhage (arrows) in totally fibrosed medulla. *Str. agalactiae* in milk secretion for five years. H & E, 45X.

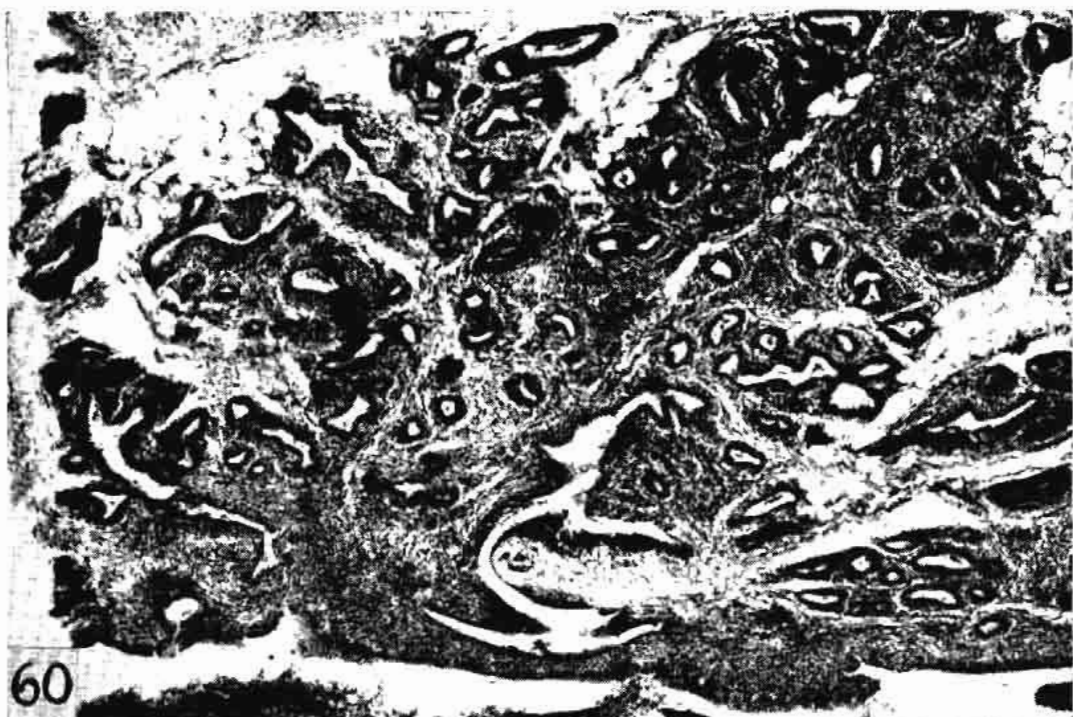

Fig. 60. Udder section from an 18-month-old heifer dead of malignant head catarrh, showing marked lymphocytic infiltration. Compare with Fig. 5. BHEY, 45X.